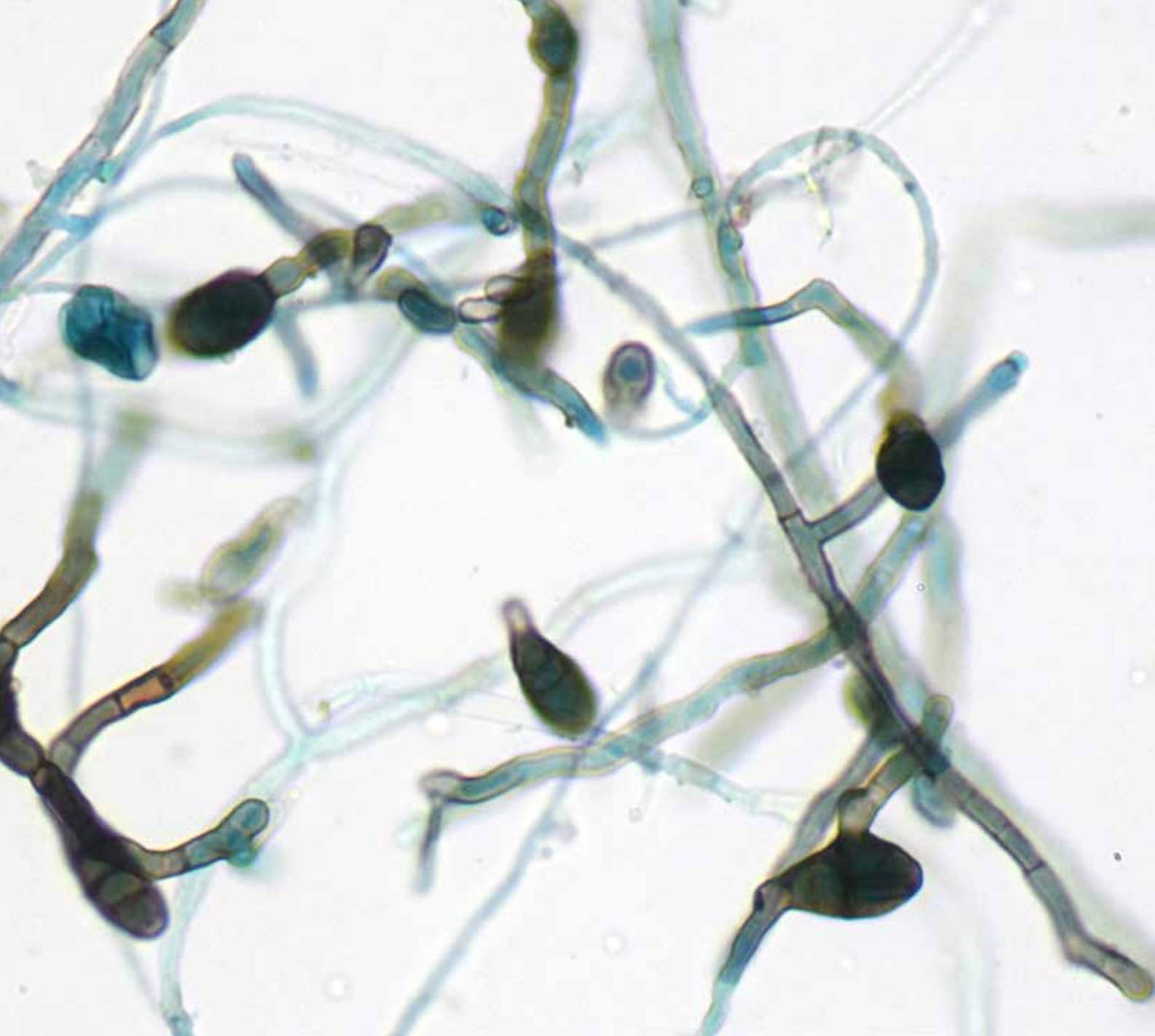



Practical Guide and Atlas for the

# Diagnosis of Fungal Infections

**Editor**

Afia Zafar

**Associate Editors**

Kausar Jabeen & Joveria Farooqi

# **Practical Guide and Atlas for the Diagnosis of Fungal Infections**

## **Editor**

Afia Zafar  
MBBS, DCP, FRCPath

## **Associate Editors**

Kausar Jabeen  
MBBS, FCPS, MSc (Medical Mycology)

Joveria Farooqi  
MBBS, FCPS, MSc (Epidemiology and Biostatistics)



THE AGA KHAN UNIVERSITY

# Foreword

I am honoured to be asked to write the Foreword for this *Practical Guide and Atlas for the Diagnosis of Fungal Infections*. Fungal infections are ubiquitous and often result in much misery and suffering. Immunocompromised patients in particular are at risk of such infections. Advances in healthcare resulting in an increasing population of immunocompromised individuals further exacerbate the risk of fungal infection related morbidity and mortality.

These infections, however, are frequently underdiagnosed and hence under-recognised. The true burden of fungal infections particularly in resource-limited countries is thus unknown. Without such baseline information it is difficult to assess the impact that such infections may have on the health of the population and to develop strategies for their control. There is thus a great need for tools that can enhance capacity for the diagnosis and control of fungal diseases.

This book written by experienced and distinguished experts in the field presents a comprehensive and a very practical approach to the laboratory diagnosis of fungal infections. The excellent illustrations and photographs accompanied by stepwise practical guidance will assist professionals and students in strengthening diagnosis of such infections. They further provide a much-needed guide to the spectrum of fungi associated with infections in this part of the world.

As the number of antifungal agents available and their spectrum of activity increases, so does the need to determine the susceptibility of isolates to these agents. Antifungal susceptibility testing is not widespread in resource-limited settings. Thus the chapter on antifungal susceptibility testing provides a detailed account of currently available susceptibility methodologies to facilitate their implementation. This book furthermore touches upon newer techniques that are being introduced for the diagnosis of fungal diseases. It also emphasises the importance of safety precautions required in mycology laboratories.

Written at the behest of many students and colleagues requesting guidance in developing capacity for diagnostic mycology, this book is timely and much needed. Based on the authors own experience in establishing diagnostic mycology in a developing country, it provides clear guidance in a very readable form. It will hopefully contribute toward enhancing the detection of fungal diseases and increasing the cadre of enthusiastic medical mycologists across the globe.

**Rumina Hasan**

**Abdulaziz Hussaini Shariff Professor**  
*MBBS, PhD, FRCPATH*

© 2017 by Aga Khan University.

All rights reserved. This book or any portion thereof may not be reproduced or used in any manner whatsoever without the express written permission of the publisher.

This publication is fully supported by a grant received from the United States Department of State and the Higher Education Commission, Pakistan through the Pakistan-US Science and Technology Cooperation Program.

For all queries, please write to:

Department of Pathology and Laboratory Medicine  
Aga Khan University  
Stadium Road, P.O. Box 3500  
Karachi 74800, Pakistan  
Fax: +92 21 3493 4294; 3493 2095  
Tel: +92 21 3486 4530 or 3493 0051 ext. 4530

ISBN 978-969-8073-34-3

## Acknowledgments

Compiling an atlas of clinically-relevant fungi in a country such as Pakistan is no small undertaking. It is a consequence of hard labour: after conducting eight hands-on workshops in fungal disease diagnosis and a six-year systematic surveillance of prevalent invasive mycoses in Pakistan, we were inspired to compile this collection as an atlas. The eventual publication of this material has been fully supported by a grant received from the U.S. Department of State and the Higher Education Commission, Pakistan through the Pakistan-U.S. Science and Technology Cooperation Program.

This effort would have been fruitless without a team of committed individuals working with us.

Dr Mary E. Brandt, then Chief of the Mycotic Diseases Branch at the Centers for Disease Control and Prevention, Atlanta, wholehearted collaboration made it possible for us to gain the direction we needed to develop the training material.

Our team including our talented scientific photographer Faisal Riaz Malik, our dedicated research officer Raunaq Mahboob, and mycology bench technologists Fahim Naqvi, Samia Tariq, Saira Latif and Kanwal Iqbal helped us achieve this daunting task, from concept to publication.

Mention must be made of our postgraduate trainees, especially Pushpa Bhawan Mal and Fizza Farooqi, whose enthusiasm ensured that all microscopic findings, colony morphologies and samples from patients were recorded for posterity. The trainees even created a group on social media for this very purpose and became quite proficient at taking photographs with cellphone cameras.

This Atlas would not have been possible without the microbiology faculty at the Aga Khan University, who both contributed to and offered endless support in producing this publication.

We also want to thank all the clinicians, infectious diseases consultants, medical microbiologists, including our own alumni, dermatologists, radiologists and other colleagues who contributed clinical and radiological images from all over Pakistan, and obtained consent from their patients on our behalf.

Notable among them are Dr Amjad Mahboob (Gajju Khan Medical College, Swabi), Dr Summiya Nizamuddin and Dr Nasim Akhtar (Shaukat Khanum Memorial Hospital, Lahore), Dr Aysha Ilyas (National Medical Center, Karachi), Dr Samreen Sarfaraz and Dr Fivzia Harekar (The Indus Hospital, Karachi) who sent specimens and isolates to our lab for diagnosis and identification, which enriched our collection and broadened our experience.

We are also grateful to Dr Nadia Jalja for her outstanding editorial skills that helped us polish this Atlas and prepare it for publication.

Last but definitely not the least, we are greatly indebted to the Aga Khan University for providing an environment which is so amenable to academic pursuits that we were able to bring forth this compilation.

**Afia Zafar**

*Editor*

# Introduction: Why You Need This Atlas

Laboratory diagnosis of fungal infections remains challenging in South East Asia as it is a neglected field in most diagnostic centres in the developing world.

Initial microscopic examination of clinical specimens for the presence of fungal elements followed by growth and eventual identification of isolates up to genus and species levels are very basic and important services that must be provided by any clinical microbiology laboratory. These services have considerable impact on selection of appropriate antifungal therapy and ultimate reduction in morbidity and mortality.

With the realisation of scarcity of this service and expertise in Pakistan, our group decided to produce an atlas for use in clinical laboratories to diagnose fungal infections as well as to improve understanding and skills of clinical laboratory technologists, residents and junior consultants.

The editors and authors are hopeful that this atlas will aid in the identification and reporting of fungi in day-to-day clinical laboratory practice.

## Contributors

### **Afia Zafar**

Professor & Consultant Microbiologist  
Pathology & Laboratory Medicine  
Aga Khan University, Karachi

### **Kausar Jabeen**

Associate Professor & Consultant Microbiologist  
Pathology & Laboratory Medicine  
Aga Khan University, Karachi

### **Joveria Farooqi**

Assistant Professor & Consultant Microbiologist  
Pathology & Laboratory Medicine  
Aga Khan University, Karachi

### **Saadia Tabassum**

Assistant Professor & Consultant Dermatologist  
Medicine  
Aga Khan University, Karachi

### **Mohammad Zeeshan**

Assistant Professor & Consultant Microbiologist  
Pathology & Laboratory Medicine  
Aga Khan University, Karachi

### **Zafar Sajjad**

Professor & Consultant Radiologist  
Radiology  
Aga Khan University, Karachi

### **Erum Khan**

Associate Professor & Consultant Microbiologist  
Pathology & Laboratory Medicine  
Aga Khan University, Karachi

### **Seema Irfan**

Associate Professor & Consultant Microbiologist  
Pathology & Laboratory Medicine  
Aga Khan University, Karachi

### **Sadia Shakoor**

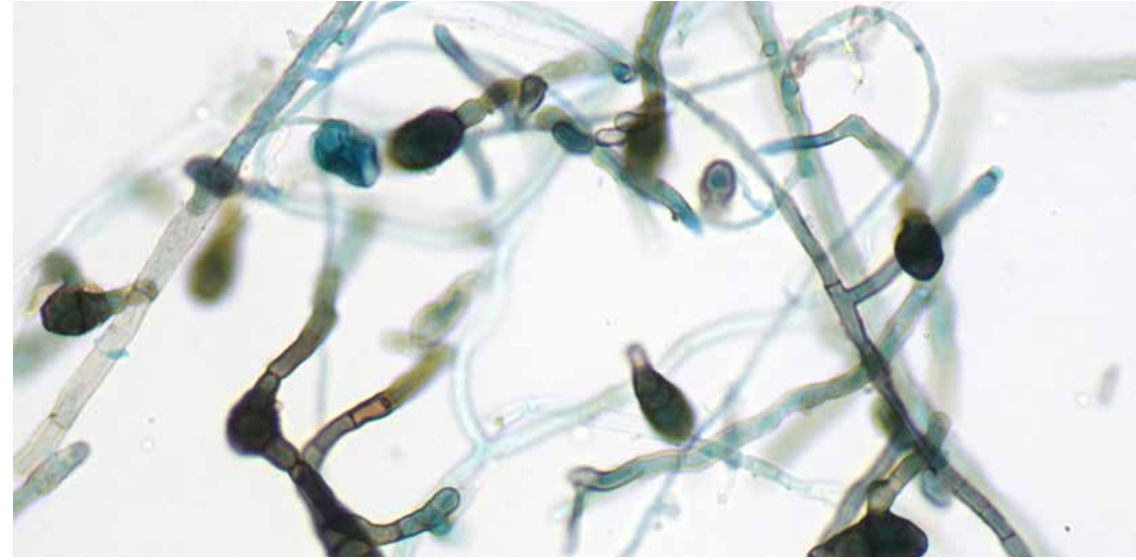
Assistant Professor & Consultant Microbiologist  
Pathology & Laboratory Medicine  
Aga Khan University, Karachi

### **Imran Ahmed**

Senior Instructor & Consultant Microbiologist  
Pathology & Laboratory Medicine  
Aga Khan University, Karachi

## Abbreviations

AFPA	<i>Aspergillus flavus</i> and <i>Aspergillus parasiticus</i> agar
ATCC	American Type Culture Collection
BHI	Brain heart infusion
BiGGY	Bismuth glycine glucose yeast agar
BSC	Biological safety cabinet
BSL-3	Biosafety Level 3 laboratory
CAP	College of American Pathologists
CDC	Centers for Disease Control and Prevention
CLSI	Clinical and Laboratory Standards Institute
CMT	Commeal Tween-80 agar
CSF	Cerebrospinal fluid
DTM	Dermatophyte test medium
EAPCRI	European Aspergillus PCR Initiative
EUCAST	European Committee on Antimicrobial Susceptibility Testing
FDA	U.S. Food and Drug Administration
H&E stain	Haematoxylin and eosin stain
IA	Invasive aspergillosis
KOH	Potassium hydroxide
LAI	Laboratory-acquired infection
LPCB	Lactophenol cotton blue
MEA	Malt extract agar
MHA	Müller-Hinton agar
MIC	Minimum inhibitory concentration
MSDS	Material safety data sheet
MTB	<i>Mycobacterium tuberculosis</i>
PAF	Partial acid-fast
PCR	Polymerase chain reaction
PDA	Potato dextrose agar
PNA-FISH	Peptide nucleic acid-fluorescence in situ hybridisation
PPE	Personal protective equipment
PT	Proficiency testing
QC	Quality control
RPMI	Roswell Park Memorial Institute medium
SBA	Sheep blood agar
SDA	Sabouraud's dextrose agar
SDAC	Sabouraud's dextrose agar with chloramphenicol
SOPs	Standard operating procedures

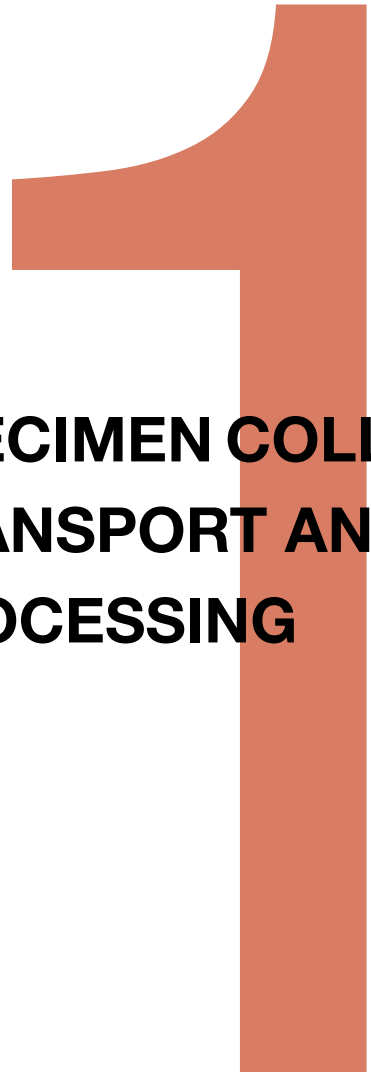

## Contents

<b>Chapter 1   Specimen Collection, Transport and Processing</b> .....	<b>- 2 -</b>
Prerequisites .....	- 2 -
Specimen Collection and Transport .....	- 2 -
Specimen Processing and Microscopy .....	- 5 -
<b>Chapter 2   Fungal Media and Cultures</b> .....	<b>- 10 -</b>
Fungal Media .....	- 10 -
Microscopic Examination of Culture .....	- 18 -
<b>Chapter 3   Diagnosis of Fungal Infections: Clinical Lesions, Microscopic Examination and Culture</b> .....	<b>- 22 -</b>
<i>Candida</i> .....	- 23 -
<i>Cryptococcus neoformans</i> .....	- 34 -
Rare yeasts .....	- 38 -
<i>Aspergillus</i> .....	- 42 -
Mucoraceous Molds .....	- 50 -
Dermatophytes .....	- 55 -
Hyaline Molds .....	- 63 -
Dematiaceous Molds and Melanised Fungi .....	- 70 -



<b>Chapter 4   Antifungal Susceptibility Testing</b> .....	<b>- 84 -</b>
Susceptibility Testing for <i>Candida</i> species .....	- 84 -
<b>Chapter 5   Antigen-based Tests for the Diagnosis of Fungal Infections</b> .....	<b>- 90 -</b>
Cryptococcal Antigen Testing .....	- 90 -
β-D-Glucan Detection .....	- 90 -
Galactomannan Detection .....	- 91 -
<b>Chapter 6   Molecular Methods for the Diagnosis of Fungal Infections</b> .....	<b>- 94 -</b>
Current Status .....	- 94 -
<b>Chapter 7   Quality Assurance</b> .....	<b>- 98 -</b>
Internal Quality Assurance .....	- 98 -
External Quality Assessment .....	- 100 -
<b>Chapter 8   Safety in the Mycology Laboratory</b> .....	<b>- 104 -</b>
Pre-Analytical Phase Hazards .....	- 104 -
Analytical Phase Hazards .....	- 104 -
Post-Analytical Phase Hazards .....	- 106 -
<b>Glossary</b> .....	<b>- 109 -</b>
<b>References and Resources</b> .....	<b>- 111 -</b>
<b>Index</b> .....	<b>- 113 -</b>



**SPECIMEN COLLECTION,  
TRANSPORT AND  
PROCESSING**

# Specimen Collection, Transport and Processing

Kauser Jabeen

The visualisation of fungal elements in invasive and sterile specimens is still considered the gold standard for diagnosis of fungal infection. Appropriate specimen collection, transport and processing are essential steps to increase the diagnostic sensitivity of these conventional tools.

## Prerequisites

- Always consult the SOP manual of the diagnostic laboratory for the particular specimen and test.
- Aim to collect sample in a sterile kit under aseptic conditions.
- Ensure that you have the appropriate swab kit (alcohol swabs, gloves, transportation tube and media).
- If it is a special or non-routine test, coordinate with the laboratory about specific requirements for collection and handling.
- Document the following:
  - Patient identifiers (e.g. name, age, medical record number);
  - Sample identifiers (e.g. swab, smear, scrape, urine, blood);
  - Location and type (e.g. lower limb wound, nail scraping, hair sample);
  - Date and time of collection;
  - Deviations from standard protocol during collection (e.g. not performed under aseptic conditions if large traumatic wound); and
  - Relevant clinical information including recent and current antimicrobial therapy.
- Ensure that adequate material (at least 2 ml of bodily fluids) is sent to the laboratory for proper yield. An inadequate specimen may lead to a false negative result.
- Transport the sample within 2 hours and process promptly for optimum recovery of fungi.
- If a delay is anticipated, refrigerate specimens at 4°C (exceptions: blood, bone marrow, CSF and sterile tissues should be stored at 35-37°C).
- Ideally, collect specimens as soon as symptoms appear and whenever possible before antifungal therapy is initiated.
- Staff must take all precautions to avoid inadvertent contamination of sample as well as for their own personal safety.

## Specimen Collection and Transport

### Swabs and Scrapings

#### Eye Swab and Scraping

- Pus and discharge samples can be collected with a cotton wool swab and sent using standard precautions to the lab.
- Due to the sensitivity of the region and serious consequences of error, only an experienced ophthalmologist collects eye samples (e.g. corneal scrapings, intraocular fluid aspirate and swabs).
- For corneal scrapings, inoculate media plates and prepare slides at the patient's side. Always contact the laboratory to obtain suitable media prior to the procedure. Alternatively, send corneal scrapings directly to the laboratory.
- Intraocular fluid (vitreous and aqueous) is collected using specialised equipment in the operating room.
- If sample is insufficient to perform both smear and inoculation of plates, give priority to culture.
- In case of contact lens-related infections, send contact lenses, case and cleaning solution to the lab for culture as well.

#### Ear Swab and Scraping

- A physician collects samples from outer and middle ear. Skin scrapings from the external auditory canal are preferred. Use a sterile swab stick to collect exudates or debris.
- For deeper ear infections and to avoid damage to the ear drum, an ENT surgeon or experienced physician should use a speculum to draw specimen.

#### Oral Swab

- Using a sterile oral swab collect exudate, pus or debris from the lesion or inflamed area within the oral cavity (mucosal surface, lips, inner side of cheek or back of throat).
- A tongue depressor/spatula aids visualisation and avoids contamination from other parts of the mouth.

#### Low and High Vaginal Swabs

- All mucous discharge should be cleared prior to sample collection.
- A low vaginal swab (LVS) can be collected by the gynaecologist or by the patient herself after receiving proper instructions from the physician.
- A gynaecologist collects high vaginal swab (HVS) using a speculum and swab stick. A smear can be made at the same time.

## Body Fluids

#### Blood

- A phlebotomist, physician or nurse can collect an intravenous sample after skin disinfection.
- In adults, two samples (10 ml each) are submitted in an aerobic and anaerobic blood culture bottle.
- In children, a single sample (4-10 ml) is submitted in a paediatric blood culture bottle.

#### Antral Washout

- Nasal irrigation or sinus washout samples are obtained under general anaesthesia by an ENT surgeon.
- Sinus contents are sent to the laboratory in a sterile container.

#### Lumbar Puncture

- With the patient lying on his side, a single sample (1-10 ml CSF) is drawn by a trained physician after giving local anaesthesia and sterile preparation of aspiration site (usually between lower lumbar spines).
- Sample is sent immediately to laboratory.

#### Urine

- Midstream sample is collected by the patient who should be instructed to:
  - Collect 10-20 ml midstream urine in a sterile container during the first morning urination.
  - Void the first portion of the urine, and then catch the rest in the container without stopping the stream.
  - Ensure hand hygiene prior to collection by washing hands thoroughly with soap and water, and then drying with a paper towel. Females should spread labia and clean the urethral meatus in a front-to-back direction.
- Catheter sample is collected by a physician or nurse.
  - Clamp hub of Foley's catheter distally.
  - Clean hub sequentially with pyodine and 70% alcohol.
  - Aspirate collected urine from the hub with a sterile needle and syringe.
  - A 24-hour urine collection and Foley's catheter tip samples are not acceptable.

## Tissue

#### Biopsy

- Surgical collection and punch biopsies may be used for skin lesions.
- If grains are visible to the naked eye, collect aseptically for smear and culture.
- Sterile normal saline should be added to the tissue to prevent drying (just enough to keep tissue moist).

## Exudates, Pus and Drainage

- A physician or staff nurse can draw sample from an open wound, ulcer or abscess.
- Always sample a representative part of the lesion.
- If possible, send several swab samples to the laboratory to allow preparation of fungal smear and inoculation of culture plates.

**Open Wound**

- Use a sterile syringe to aspirate the wound deeply or alternatively use a sterile swab stick to collect sample, especially at base and advancing margins.
- Do not swab dry crusted areas as it is unlikely to yield the causative pathogen.

**Ulcer**

- Prior to specimen collection from an ulcer, remove all debris and thoroughly wash with normal saline.
- Draw a biopsy specimen from the edge of the wound or, preferably, aspirate with a needle.

**Abscess**

- Clean skin with 70% alcohol and palpate point of highest fluctuation.
- Insert sterile syringe needle and aspirate fluid from the most fluctuant point.
- If needed, obtain sample from base of lesion and abscess wall (scrapings, punch biopsy).
- Discard syringe needle before transportation to laboratory.

**Respiratory Tract Secretions****Sputum**

- Patient submits the first morning expectorated sample (optimal) with the following instructions:
  - Clean mouth with several rinses of sterile saline or water.
  - Cough out 2-5 ml of sputum (not saliva) in a wide-mouthed sterile container.
- In case of dry cough, perform sputum induction with hypertonic saline nebulisation.
- Acceptability of sputum is determined with a Gram stained smear (pus cells >25/LPF, epithelial cells <10/HPF) and only representative samples are accepted.
- 24-hour sputum collections are not acceptable.

**Tracheal Aspirate**

- Tracheal aspirates are collected through an endotracheal tube and are subject to the same limitations as sputum specimens.

**Non-Directed Bronchoalveolar Lavage**

- This method provides a lower respiratory tract sample without the need for bronchoscopy.
- A trained physician passes a suction catheter down the endotracheal tube until resistance is met.
- Inject an aliquot of sterile saline and then aspirate at least 1 ml of secretions.
- Non-directed techniques have been found to give results comparable to bronchoscopic methods.

**Dermatological Specimens****Skin Scrapings**

- Clean skin with 70% alcohol.
- Scrape edges of lesion (as edge has greatest amount of viable fungus) with a blunt scalpel blade.
- Collect skin scales in a sterile petri dish or similar wide-mouthed container or alternatively, skin scrapings may be collected in a clean, dry piece of paper folded securely with Scotch tape and labelled properly.
- If a skin scraping does not yield sufficient material, then a swab or Scotch tape could be pressed on the lesion.

Collecting skin scrapings from toe web.

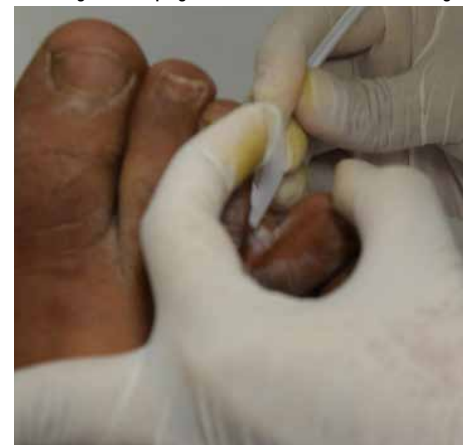

Fig. 1.1 Transferring the collected material to a sterile petri dish. Fig. 1.2

**Nail**

- Clean nail with 70% alcohol.
- Examine for damaged, discoloured, brittle or dystrophic area.
- Material should be taken from the affected areas.
- Entire thickness of the damaged nail should be cut as far back as possible. Any crumbly material or material under the nail should be collected and sent in a sterile container.
- If skin lesions are present they should be scraped and the material collected should be sent separately.

**Hair and Scalp**

- A Wood's light, if available, may be helpful in selecting specimens.
- Pluck broken or lustreless hairs from periphery of lesion. Scrape scalp from edge of hair loss area.
- Do not cut hair.
- If hair are broken off (endothrix), it often may be necessary to scrape the coiled hair stubble from the scalp with a sterile blade or slide edge, rather than plucking with tweezers.
- In piedra infections, cut infected hair with scissors.
- Submit specimen to laboratory in sterile petri dish.

**Specimen Processing and Microscopy**

- Ensure that at the time of receipt of sample, documentation is complete, including provision of relevant history for interpretation of results.
- Determine acceptability and adequacy of specimen.
  - If specimen collection did not comply with protocol or sample is inadequate for multiple tests to be performed simultaneously, immediately inform referring physician.
  - Prioritise performing sensitivity and culture to other tests, except for nails and skin scrapings from suspected tinea versicolor.
- Visually inspect the specimen to observe necrosis, purulence and grains.
- To improve sensitivity, use most purulent, necrotic and blackened portion of specimen for smear preparation and culture inoculation.
- Inoculate swab specimens directly on the surface of appropriate media.
- Issue reports of fungal smear on the presence and description of fungal elements the same day.
- Positive culture results of samples from CSF, sterile body fluids, tissues and other significant sites should be informed to clinicians as soon as possible.

**Box 1.1: Factors increasing diagnostic sensitivity**

- Examination of a large amount of tissue or other materials
- Selection of necrotic, purulent or caseous material
- Use of optical brighteners
- Centrifugation
- Development of expertise

**Table 1.1: Specimen processing requirements and appropriate microscopy techniques**

Specimen type	Specimen processing	Direct microscopy techniques
<i>Fluids</i>		
Blood culture	<ul style="list-style-type: none"> <li>• Incubate 2 bottles at 37°C in an automated system.</li> <li>• Perform microscopy and subculture once positive.</li> </ul>	<ul style="list-style-type: none"> <li>• Gram stain</li> <li>• 10% KOH wet mount</li> <li>• India ink</li> <li>• PAF stain (for gram positive branching rods such as <i>Nocardia</i>, <i>Actinomyces</i> etc.)</li> </ul>
CSF and other sterile body fluids	<ul style="list-style-type: none"> <li>• Centrifuge CSF in sterile tube at 2000-2500 rpm for 10 minutes.</li> <li>• Pour the supernatant back into the collection container and store for antigen detection.</li> <li>• The pellet is used for smear and wet mount and for subsequent culture.</li> </ul>	<ul style="list-style-type: none"> <li>• Gram stain</li> <li>• 10% KOH wet mount</li> <li>• India ink</li> <li>• PAF stain</li> </ul>
<i>Tissue and Swabs</i>		
Biopsy	<ul style="list-style-type: none"> <li>• Mince using a sterile blade after placing tissue in a sterile petri plate (grinding will inhibit growth of mucoraceous molds).</li> <li>• Inoculate tissue on culture plates.</li> </ul>	<ul style="list-style-type: none"> <li>• Gram stain</li> <li>• 10% KOH wet mount</li> <li>• India ink</li> <li>• PAF stain</li> <li>• Calcofluor white stain</li> </ul>
Swabs	<ul style="list-style-type: none"> <li>• Directly inoculate onto media.</li> <li>• If there is insufficient material, a small amount of normal saline can be added to re-suspend material.</li> <li>• If granules are visualised, wash, centrifuge and crush for processing.</li> </ul>	<ul style="list-style-type: none"> <li>• Gram stain</li> <li>• 10% KOH wet mount</li> <li>• India ink</li> <li>• PAF stain</li> <li>• Calcofluor white stain</li> </ul>
<i>Respiratory tract secretions</i>		
Sputum and tracheal aspirates	<ul style="list-style-type: none"> <li>• Mix equal volume of sputasol and vortex till specimen is liquefied.</li> <li>• Centrifuge at 1200 g for 10 minutes.</li> <li>• Discard supernatant and re-suspend centrifuged deposit.</li> <li>• Use 1 drop of sediment for microscopy and media inoculation.</li> <li>• Alternatively, directly inoculate on culture media, without pre-treatment.</li> </ul>	<ul style="list-style-type: none"> <li>• Gram stain</li> <li>• 10% KOH wet mount</li> <li>• India ink</li> <li>• PAF stain</li> <li>• Calcofluor white stain</li> </ul>

Bronchoalveolar lavage, bronchoscopy aspirates/ washings	<ul style="list-style-type: none"> <li>• Centrifuge at 1200 g for 10 minutes.</li> <li>• Discard supernatant and re-suspend centrifuged deposit.</li> <li>• Use 1 drop of sediment for microscopy and media inoculation.</li> </ul>	<ul style="list-style-type: none"> <li>• Gram stain</li> <li>• 10% KOH wet mount</li> <li>• India ink</li> <li>• PAF stain</li> <li>• Calcofluor white stain</li> </ul>
--	---	---

*Dermatological specimens*

Skin scrapings	<ul style="list-style-type: none"> <li>• Placed directly on the agar surface using sterile forceps.</li> <li>• Press lightly in to agar surface.</li> </ul>	<ul style="list-style-type: none"> <li>• 10% KOH wet mount</li> <li>• Calcofluor white stain</li> </ul>
Nail	<ul style="list-style-type: none"> <li>• Cut into small pieces with the scalpel or sterile blade.</li> <li>• Place directly on the agar surface using sterile forceps.</li> <li>• Press lightly in to agar surface.</li> </ul>	<ul style="list-style-type: none"> <li>• 10% KOH wet mount</li> <li>• Calcofluor white stain</li> </ul>
Hair and scalp	<ul style="list-style-type: none"> <li>• Cut strands of hair into 1 mm lengths with a scalpel or sterile blade.</li> <li>• Press lightly into selective media with sterile forceps.</li> </ul>	<ul style="list-style-type: none"> <li>• 10% KOH wet mount</li> <li>• Calcofluor white stain</li> </ul>

**Table 1.2: Stains for microscopic examination of clinical material**

Principle	Procedure	Controls
<i>Gram stain</i>		
Stains walls containing protein-sugar complexes called peptidoglycan. Typically have low lipid content. Gram positive fungi stain violet. Gram negative fungi decolourise and stain pink with safranin.	<ul style="list-style-type: none"> <li>• Heat-fix the smear.</li> <li>• Apply crystal violet stain to the smear for 30 seconds. Drain stain and wash with water.</li> <li>• Add Gram's Iodine for 30 seconds and the drain excess.</li> <li>• Decolourise with 95% ethyl alcohol.</li> <li>• Counterstain with safranin for 30 seconds and then drain excess.</li> <li>• Rinse and allow to air dry.</li> <li>• Examine under microscope.</li> </ul>	<ul style="list-style-type: none"> <li>• Positive control: <i>Staphylococcus aureus</i></li> <li>• Negative control: <i>Escherichia coli</i></li> </ul>
<i>10% potassium hydroxide (KOH) wet mount</i>		
Dissolves keratin and proteinaceous components of tissue. Makes fungal elements prominent.	<ul style="list-style-type: none"> <li>• Place specimen on slide.</li> <li>• Add a drop of 10% KOH.</li> <li>• Apply coverslip and gently warm the slide over a flame or warmer. Alternatively leave the slide at room temperature for 10 minutes.</li> <li>• Gently press the coverslip to spread the already softened tissue evenly on the slide.</li> <li>• Examine under a microscope.</li> </ul>	Control: <i>Aspergillus</i> spp.

*Calcofluor white stain*

Binds to chitin and cellulose in fungal cell wall. Better visualisation of fungal elements than 10% KOH. Fungal elements appear bright apple green.

- Prepare a smear from specimen.
- Add 1 drop of Calcofluor white stain.
- Add 1 drop of 10% KOH for thick specimens, cutaneous specimens and tissue.
- Apply coverslip and allow the slide to remain at room temperature for 5 minutes.
- Examine slide under fluorescent microscope using manufacturer's recommendation for wavelength and filter.
- Positive control: *Aspergillus* spp.
- Negative control: *E. coli*

*India ink*

Negative staining method. Used to detect encapsulated strains of *Cryptococcus*. This stain could also be performed with suspected *Cryptococcus* colonies. Small portion of isolated colony should be emulsified in India ink. Some strains of *C. neoformans*, as well as other Cryptococci may not produce discernible capsules in vitro.

- Place a small drop of India ink on a slide.
- Fluid and CSF should be centrifuged and a small amount of this should be mixed with India ink.
- In thick specimens like pus and sputum a drop of 10% KOH along with India ink improves visualisation.
- Leukocytes, fat droplets, and tissue cells may look like *C. neoformans* cells. Leukocytes and tissue cells can be dissolved by adding a drop of 10% KOH.
- Positive control: *C. neoformans*
- Negative control: *C. albicans*

*Acid-fast stain (Ziehl-Neelsen stain)*

Mycolic acid is a waxy lipid that makes cell walls highly durable. Acid-fast walls only stain with carbol-fuchsin stain after being heat-treated and do not decolourise with acid-alcohol solvent.

Acid-fast organisms stain pink. Non-acid fast organisms stain blue. Partially acid-fast organisms stain pink to purple.

- Prepare heat-fixed fungal smear.
- Stain with carbol fuchsin.
- Heat stain until vapour just begins to rise (60°C).
- Allow the heated stain to remain on the slide for 5 minutes. Wash stain with distilled water.
- Cover the smear with 3% acid alcohol for 5 minutes or until the smear is sufficiently decolourised. Wash with distilled water.
- Cover the smear with malachite green stain for 1-2 minutes, using longer time when the smear is thin. Wash off stain with distilled water.
- Allow to air dry.
- Examine the smear under a microscope.
- Positive control: *M. tuberculosis*
- Negative control: *E. coli*

*Lactophenol cotton blue*

Used for visualisation of fungal elements and structures. Mainly performed from fungal colonies and used for identification. In case of non-availability of Calcofluor white stain, this can also be used for microscopic examination of clinical specimens.

- Place 1 drop of LPCB on slide.
- Immerse fungal colonies with help of Scotch tape or tease mount.
- Apply coverslip.
- Visualise under microscope.
- Controls: *A. niger*, *T. mentagrophytes*



# FUNGAL MEDIA AND CULTURES

## Fungal Media and Cultures

Mohammad Zeeshan and Seema Irfan

Once the specimen has been received, the next step is preparation of slides for microscopic examination and inoculation of appropriate culture media. There are a few principles that must always be kept in mind: always inoculate the enriched media first with the clinical specimen followed by inoculation of selective media; 2 sets of media should be inoculated, with 1 set incubated at 25-30°C and a duplicate set at 35 ± 2°C.

**Table 2.1: Types of media**

Enriched media	Supports rapid growth of pathogenic and non-pathogenic fungi.	<ul style="list-style-type: none"> <li>SBA</li> </ul>
Selective media	Contains chemicals and antibiotics that only allow the growth of certain fungi and inhibit the growth of saprophytic molds and bacteria respectively.	<ul style="list-style-type: none"> <li>SDA</li> <li>Chromogenic BIGGY agar</li> <li>Mycosel</li> </ul>
Differential media	Differentiates between closely related fungal species.	<ul style="list-style-type: none"> <li>Chromogenic BIGGY agar</li> <li>CHROMagar</li> <li>DTM</li> </ul>
Media for sporulation	Induces sporulation and helps in identification.	<ul style="list-style-type: none"> <li>CMT</li> <li>PDA</li> <li>Water agar</li> </ul>

### Fungal Media

The yield of most fungi is improved by direct culture of samples on fungal media. Cultures may be negative on bacterial media for some fungi, such as *Histoplasma*, *Mucorales* and *Coccidioides* spp. Similarly, culture of *Aspergillus* spp. on bacterial media is 30% less effective than on fungal media. Common fungal media and tests used are:

- Sabouraud's dextrose agar
- Mycobiotic or Mycosel agar
- Cornmeal Tween-80 agar
- Chromogenic BIGGY agar
- Dermatophyte test medium
- Water agar
- Christensen's urea agar (urease test)
- Germ tube test

#### Sabouraud's Dextrose Agar (With or Without Antibiotic)

Sabouraud's dextrose agar (SDA) is a universal primary medium for fungal culture. The original version of the agar was composed by Sabouraud's to isolate dermatophytes from non-sterile specimens, and was a low pH (5.6) medium with high dextrose content (4%), casein and animal peptic digest. The Emmons modification decreased dextrose to 2% and made the pH neutral (6.9-7.0). Other modifications since have included addition of various antibiotics and antifungals to change its selectivity and make it suitable for a variety of specimens.

##### Procedure

- Pour the clear slightly amber tinged medium into tubes as a slant or on petri plates.
- Inoculate tissue and fungal isolates by stabbing into the medium.
- Streak fluid specimens such as pus, aspirates, yeast isolates and yeast-like fungi in to quadrants.
- For plates inoculated directly from specimen, incubate at 25 °C, 30 °C and 37 °C.
- For temperature tolerance studies, incubate at an even wider range of temperatures (15-55 °C).
- Since SDA is a primary fungal culture medium, duration of incubation may be several weeks.

##### Interpretation

- Description of the colony's forward and reverse surface and any diffusible pigment into the medium should be noted.

##### Limitations

- Addition of selective substances may not allow certain fungi to grow easily. On the other hand, SDA without antibiotic may not inhibit highly resilient bacteria in the specimen, making isolation of fungi a challenge.

##### Quality Control

- Positive control: growth of *C. albicans* and *T. mentagrophytes*
- Negative control: no growth of *E. coli*

#### Mycobiotic or Mycosel Agar

Mycobiotic or Mycosel selective medium principally formulated for the isolation of dermatophytes but also used for the isolation of other pathogenic fungi from specimens contaminated with saprophytic fungi and bacteria. The medium consists primarily of peptones from a pancreatic digest of soybean meal and dextrose. The selective agents are cycloheximide and chloramphenicol. Cycloheximide inhibits the faster-growing saprophytic fungi. Chloramphenicol inhibits Gram-negative and Gram-positive organisms. Susceptibility to cycloheximide may be used for identification of fungi.

##### Procedure

- Direct inoculation from specimen
  - Inoculate and streak the specimen as soon as possible after it is received in the laboratory.
  - Incubate the plates at 25-30 °C in an inverted position with increased humidity for 30 days or longer in an aerobic atmosphere.
  - Examine media for fungal colonies exhibiting typical colour and morphology.
- Cycloheximide susceptibility test
  - Make a suspension of pure colony of *Candida* species in distilled water (about 1.0 McFarland turbidity).
  - Streak a loop full suspension on the agar plate in the following sequence to avoid transfer of cycloheximide to control plate.
    - SDA
    - Mycobiotic or Mycosel agar
  - Incubate at room temperature for 3 days.
  - Observe both cultures for growth and record as equal to (=) or inhibited (-) or growth on Mycosel (+).

##### Interpretation

- Direct inoculation from specimen
  - Positive: growth on plate.
  - Negative: no growth on plate.
- Cycloheximide susceptibility test
  - Positive: growth on Mycosel equal to growth on SDA.
  - Negative: no growth on the Mycosel plate or less growth on Mycosel agar than on SDA.
  - NOTE: the test should not be read after 3 days as sensitive strains may begin to grow on Mycosel agar, and false positive result may be seen.

##### Limitations

- Cycloheximide in the plate is also inhibitory to some clinically relevant species. These include some *Candida* species, *A. fumigatus*, mucoraceous fungi, and *C. neoformans*.

##### Quality Control

- For growth
  - C. albicans* good growth.
  - Staphylococcus aureus* complete inhibition.
- Cycloheximide susceptibility test
  - Positive control: *T. mentagrophytes* and *C. albicans*.
  - Negative control: *A. niger*.

### Cornmeal Tween-80 Agar

CMT agar is a well-established medium used for cultivation of fungi as well as to study chlamydo-spores production by *Candida* species and other yeasts.

#### Procedure

- Pick a single colony of yeast from plate using a sterile straight wire.
- Make three parallel cuts ¼ inch or 1 cm apart on the surface of the agar, holding the inoculating wire at approximately 45° angle.
- Using sterile forceps, place a coverslip over the cross. Reduced oxygen tension stimulates chlamydo-spore production.
- Invert plate and incubate up to 2-3 days (96 hours) at 25 ± 2°C.

#### Interpretation

- Using low power objective of microscope, scan the growth on CMT agar.
- Determine at the outset if pseudohyphae are present. The observation of pseudohyphae and blastoconidia put an unknown isolate into the genus *Candida*.
- Examine plates daily for the development of chlamydo-spores.

#### Limitations

- None of the cornmeal agar patterns are diagnostic with the exception of chlamydo-spore production by *C. albicans*.
- Subculture where necessary and perform appropriate biochemical tests for further identification.

#### Quality Control

- Set up known controls.
- *C. albicans*: good growth, white colonies and chlamydo-spores production.
- *C. krusei*: good growth, white to cream colonies but no chlamydo-spores production.

### Chromogenic Bismuth Glycine Glucose Yeast (BiGGY) Agar

BiGGY agar is a partially selective and differential medium for the cultivation and identification of *Candida* species from pure cultures or clinical specimens. *Candida* species, through a process of substrate reduction, reduces the bismuth salt to bismuth and sulfite to sulfide. Bismuth and sulfide combine to form a brownish to black precipitate that stains colonies and may diffuse into the medium. Also bismuth and sulfur compounds are inhibitory to many bacteria. Yeast extract and glucose provide essential nutrients for growth. Glycine is an additional nutrient, but also inhibits many bacterial species at the high concentration used in this medium.

#### Procedure:

- Inoculate specimen on media as soon as it is submitted using streak plate technique when isolating pure cultures from specimens containing mixed flora.
- If culture is drawn from swab, then roll swab over a small area of the surface at the edge and then streak from this inoculated area. Streak in all four corners.
- Invert plate and incubate at 35 ± 2°C aerobically for 24-48 hours and observe daily for 5 days.

#### Interpretation

- *C. albicans*: smooth, round brown-black colonies with mycelial fringe without sheen or any diffusible pigment into surrounding media.
- *C. tropicalis*: smooth, dark brown to black colonies with a metallic sheen.
- *C. krusei*: large, flat, shiny, wrinkled brown-black colonies with yellow diffusible pigment.

#### Limitations

- Further testing should be performed on colonies from pure culture for complete identification.
- Some bacteria may grow on the agar but can be differentiated from yeast using microscopy.

#### Quality Control

- *C. albicans*, *C. krusei*, *C. tropicalis*: characteristic colonies.
- *E. coli*: complete or partial growth inhibition.

### Dermatophyte Test Medium

Dermatophyte test medium is used as a screening medium for the recovery, selection and differentiation of dermatophytes (*Microsporum*, *Trichophyton* and *Epidermophyton*) from keratinous specimens (hair, skin and nails). Nitrogenous and carbonaceous compounds are provided by soy peptone. Cycloheximide inhibits saprophytic molds while chloramphenicol and gentamicin inhibits Gram-negative and positive bacteria. The medium is yellow and turns red with growth of dermatophytes due to the presence of phenol red indicator.

#### Procedure

- Skin scraping
  - Place the specimen directly on the agar surface using sterile forceps. It should be pressed into the agar slightly.
- Nail
  - Cut into small piece with the scalpel or sterile blade placed directly on the agar surface using sterile forceps. It should be pressed into the agar slightly.
  - Incubate plate at 25°C for 2 weeks.
  - Examine plate daily for the presence of growth and pigment.

#### Interpretation

- Positive: growth and red pigment production.
- Negative: no growth.

#### Limitations

- Prolonged incubation may cause deterioration on antibiotics in the media and therefore cause the overgrowth of saprophytic molds.

#### Quality Control

- Positive control
  - *T. mentagrophytes* fair to good growth, alkaline (red pigment).
- Negative control
  - *P. aeruginosa* partial to complete inhibition.
  - *A. niger* partial to complete inhibition.

### Water Agar

Water agar is a nutritionally-deficient media known to enhance production of spores and conidia of sporulation.

#### Media Preparation

- Mix 20 grams of agar in 1 litre of distilled water.
- Bring reagents to a boil.
- Autoclave at 15 lb/in<sup>2</sup> for 15 minutes.
- Cool in slanted position or store as butts to be melted down and used as slants or plates as needed.

#### Procedure

- Using a sterile loop, pick a small sample from colony margin.
- Emulsify the colony in sterile normal saline.
- Transfer a drop from normal saline to water agar plate. Do not streak and allow the drop to be absorbed in the media.
- Wrap a paraffin film around the sides of the plate to cover the opening (or use masking tape to hold the lid down).
- Incubate the water agar plate at room temperature.

#### Interpretation

- As the colony grows, observe sporulation with LPCB preparation.

#### Limitations

- In case of infection due to more than one agent, the strain that grows in a more limited manner may pass unnoticed for a long period. Therefore streak on fresh selective culture plates to identify individual colonies.

**Quality Control**

- Cultural Response: cultural characteristics observed after 48-72 hours incubation at 25-30°C.
  - *C. albicans*: fair to good growth.
  - *Saccharomyces cerevisiae*: fair to good growth.

**Christensen's Urea Agar (Urease Test)**

Urea agar is used for the differentiation of the yeast-like fungi and also in the identification of aerobic *Actinomycetes* and *Trichophyton* species. Breakdown of urea by urease producing fungi release ammonia, with increase in pH leading to colour change of medium from yellow (pH 6.8) to red (pH 8.1).

**Procedure**

- Inoculate the urea agar slope with heavy amount of pure culture.
- Observe at 24 to 48 hours for yeast and 1 week for dermatophytes.

**Interpretation**

- Positive: urea positive organism produces alkaline reaction indicated by pink colour.
- Negative: no colour change.

**Limitations**

- Bacterial contamination may cause false positive reaction.

**Quality Control**

- Positive control: *C. neoformans*.
- Negative control: *C. albicans*.

**Germ Tube Test**

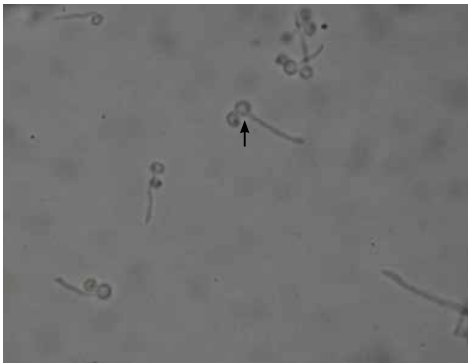Germ tube test is used for differentiation of *C. albicans* from other *Candida* species. Approximately 95-97% of *C. albicans* develop germ tubes when incubated in serum.

**Procedure**

- Pick a small sample from yeast colony and gently emulsify with 3-4 drops of serum in a small glass tube. (Note: a large colony sample inhibits germ tube formation.)
- Incubate the tube at 37°C for 2 hours. Be careful as increasing the period of incubation leads to false positive results.
- Transfer a drop of serum onto a slide for examination.
- Place a coverslip and examine slide under microscope at low (x10) and high power (x40) objectives.

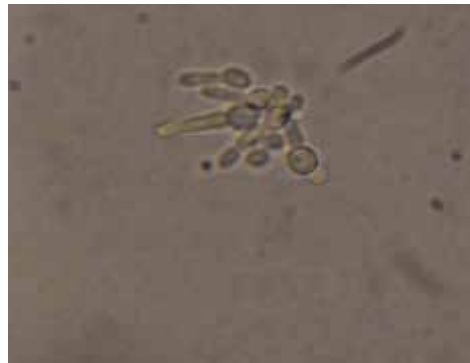Germ tube test positive: true hyphae arising from yeast cell.

Fig. 2.1



Germ tube test negative: pseudohyphae arising from yeast cells.

Fig. 2.2



**Interpretation**

- Positive test: A germ tube emerges laterally from a yeast cell, without constriction at the point of origin, e.g. *C. albicans* and *C. dubliniensis* (Fig 2.1).
- Negative test: If there are yeast cells only or extension from a yeast cell with constriction at the point of origin, e.g. *C. tropicalis*, *C. glabrata* and other yeasts (Fig 2.2).

**Limitations**

- Early pseudohyphae formation as seen in *C. tropicalis* may be falsely interpreted as germ tube formation.
- This test is only for preliminary identification and requires definitive identification.

**Quality Control**

- *C. albicans*: positive control.
- *C. tropicalis*: negative control.

**Fungal Culture: Selection, Preparation and Reading**

- For isolation of fungi from potentially contaminated specimens, simultaneously inoculate a nonselective medium and a selective medium.
- Sort and place new cultures slip in numerical order. Separate according to reading schedule and length of incubation. Prolonged incubation may cause drying of media, therefore secure with paper tape around the whole circumference of the plate.
- Examine cultures daily to observe the rate of growth, gross colony morphology and physical changes or contamination in media.
- Once fungal culture plates have been examined, place them in appropriate stacks and re-incubate.
  - Remove any culture medium showing fungal growth for further work-up.
  - Correlate with culture sample submitted in the bacteriology section of laboratory.
  - Note any contamination and record on the slip.
  - A senior mycology technologist/consultant should also review the growth for interpretation.
  - Cerebrospinal fluid, blood, samples from sterile sites and special request specimen cultures should be read daily for the first 2 weeks and 2 times a week for the next 2 weeks.
  - Positive specimens are worked up immediately.
  - Any bacterial growth in these samples should also be shown to a senior mycology technologist/consultant for appropriate action.
- Routine screening of all other fungal cultures should be done daily for the first week and 2 times a week for the remaining incubation period.
  - Any mold referred from the bacteriology section is processed and worked up the same day.
  - All final cultures should be reviewed and signed by a senior mycology technologist/consultant.

**Table 2.2: Types of fungal media and properties**

Type of media	Properties	pH	Incubation	Comments
Sheep blood agar	General purpose enrichment media	7.4 ± 0.2	37°C aerobically	
Sabouraud's dextrose agar without antibiotic	General purpose enrichment media	5.6 ± 0.2	37°C and 28°C aerobically	<ul style="list-style-type: none"> <li>• Low pH and high dextrose content enhance fungal growth and inhibit bacterial growth.</li> <li>• Incubate at different temperatures in order to observe the rate of growth.</li> <li>• Dextrose is used as a source of energy.</li> </ul>
Sabouraud's dextrose agar with chloramphenicol	Enrichment media Selective (0.5% chloramphenicol)	5.6 ± 0.2	25-30°C aerobically	<ul style="list-style-type: none"> <li>• With the addition of antibiotic becomes more selective and helps in isolation of yeasts, molds, dermatophytes and <i>Nocardia</i>.</li> </ul>

Mycobiotic or Mycosel agar	Enrichment media Selective (chloramphenicol & cyclohexamide)	6.9 ± 0.2	25-30°C aerobically	<ul style="list-style-type: none"> <li>Cyclohexamide inhibits the faster-growing saprophytic fungi but is also inhibitory to some clinically-relevant species include some <i>Candida</i> and <i>Aspergillus</i> species, mucoraceous fungi and <i>C. neoformans</i>.</li> <li>Chloramphenicol inhibits Gram-negative and Gram-positive organisms.</li> <li>Reading after 72 hours is not reliable.</li> </ul>
Potato dextrose agar	General purpose sporulation medium Selective (tartaric 10%)	3.5 ± 0.1	25-30°C aerobically	<ul style="list-style-type: none"> <li>Very low pH with tartaric acid inhibits bacterial growth.</li> <li>Stimulates conidium production in fungi.</li> <li>Stimulates pigmentation production in some dermatophytes.</li> </ul>
CMT agar	General purpose and sporulation medium	6.0 ± 0.2	25-30°C aerobically	<ul style="list-style-type: none"> <li>Tween-80 is incorporated for the demonstration of pseudohyphae, chlamydospore and arthrospore formation.</li> <li>Chlamydospore production is best obtained if the yeast inoculum is placed under a coverslip or following subsurface inoculation creating a microaerophilic environment.</li> </ul>
Dermatophyte test medium	Selective (chloramphenicol & cyclohexamide) Differential	5.5 ± 0.2	25-30°C aerobically	<ul style="list-style-type: none"> <li>Cyclohexamide inhibits saprophytic molds, chloramphenicol inhibits bacteria.</li> <li>The morphology and microscopic characteristics are easily identified with this medium.</li> <li>Presence of phenol red indicator.</li> <li>The medium is yellow and turns red with growth of dermatophytes.</li> </ul>
Bismuth glycine glucose yeast agar	Selective Differential	6.8 ± 0.2	37°C aerobically 48-72 hours	<ul style="list-style-type: none"> <li>Final identification with biochemical and morphological tests needed.</li> </ul>
CHROMagar	Selective Differential	5.9 ± 0.2	35 ± 2°C aerobically 24-48 hours	<ul style="list-style-type: none"> <li>Examine plate for amount of growth and colour formation.</li> <li>Isolation and presumptive identification of yeast and filamentous fungi.</li> <li>Differentiation of <i>C. albicans</i>, <i>C. tropicalis</i> and <i>C. krusei</i>.</li> <li>Due to the differences in morphology and colours of the yeast colonies, this medium facilitates the detection of mixed yeast cultures in specimens.</li> </ul>

Christensen's urea agar	Identification	6.7 ± 0.2	25-30°C aerobically	<ul style="list-style-type: none"> <li>The ability to hydrolyse urea is an important phenotypic characteristic for the presumptive identification of</li> <li><i>Cryptococcus</i>, <i>Trichosporon</i> and <i>Rhodotorula</i> spp.</li> <li>Differentiates between <i>T. mentagrophytes</i> and <i>T. rubrum</i>.</li> <li>The medium contains 2% urea with phenol red serving as the indicator.</li> </ul>
-------------------------	----------------	-----------	---------------------	---

**Table 2.3: Specimen-specific requirements for culture, media and reading frequency**

Standard media inoculated	Aerobic incubation		Reading of culture	Target organism and fungal element
	Temperature	Report		
<i>All tissue samples and body fluids (except CSF)</i>				
2 SDAC 1 Mycosel 1 PDA 1 SBA 1 CHROMagar/BiGGY	1 SDAC, SBA, CHROMagar/BiGGY at 35-37°C	4 weeks Usually isolates appear in 48-96 hours; some organisms may take longer.	Daily for first week, then twice weekly for the next 3-4 weeks.	<ul style="list-style-type: none"> <li>Yeast</li> <li>Filamentous fungi</li> <li>Dimorphic fungi</li> </ul>
<i>CSF</i>				
2 SDAC 1 SBA 1 CHROMagar/BiGGY if smear positive for yeast	1 SDAC, SBA, CHROMagar/BiGGY at 35-37°C  1 SDAC at 22-26°C	4 weeks Usually isolates appear in 48-96 hours.	Daily for the first 2 weeks, then twice weekly for the next 3-4 weeks.	<ul style="list-style-type: none"> <li><i>Cryptococcus</i></li> <li><i>Candida</i></li> <li>Aerobic actinomycetes</li> <li>Filamentous molds</li> </ul>
<i>Respiratory tract secretions</i>				
2 SDAC 1 Mycosel 1 PDA 1 SBA	1 SDAC, SBA at 35-37°C  1 SDAC, PDA, Mycosel at 22-26°C	4 weeks Usually isolates appear in 48-96 hours.	Daily for the first weeks, then twice weekly for the next 3-4 weeks.	<ul style="list-style-type: none"> <li>Yeast</li> <li>Filamentous fungi</li> <li>Dimorphic fungi</li> </ul>

<i>Blood and bone marrow culture</i>				
Blood culture bottles containing brain heart infusion (BHI) broth	35-37°C	Keep in Bactec automated system for 4 weeks.	Daily for the first weeks, then twice weekly for the next 3-4 weeks.	<ul style="list-style-type: none"> <li>• Yeast</li> <li>• Filamentous fungi</li> <li>• Dimorphic fungi</li> </ul>
Subculture on SDA, SBA, Mycosel and CHROMagar/Biggy if smear positive for yeast		If no growth after 7 days, subculture on SBA every week for the next 3-4 weeks.		
On SBA only if smear negative		Keep subculture for 72 hours.		
<i>Dermatological specimens</i>				
1 DTM 2 SDAC 1 Mycosel	1 SDAC at 35-37°C  1 SDAC, DTM, Mycosel at 22-26°C	4 weeks Usually colonies appear in 7-10 days.	Daily for first week, then twice weekly for the next 3 weeks.	<ul style="list-style-type: none"> <li>• Dermatophytes</li> <li>• Yeasts</li> <li>• Saprophytes as superimposed infective agents</li> </ul>

### Microscopic Examination of Culture

An essential feature of fungal identification is the microscopic morphology of the isolate. The common techniques used for observing fungal culture under the microscope are given below.

#### Tease Mount Preparation

- Place a clean glass slide on the work bench and put a small drop of LPCB solution in the middle of the slide.
- Remove a fragment of a fungal colony (approximately 1-2 mm from the periphery) with a wooden stick and place on the LPCB solution.
- Gently tease the fragment with two wooden sticks until it has been separated.
- Gently place a coverslip over it. Do not tap or push down as this may dislodge conidia from conidiophores.
- Carefully examine the slide under low (x10) and high power (x40) objectives of the microscope for the characteristic shape and arrangement of the spores, hyphae, budding yeasts etc.
- For a permanent preparation, rim the coverslip with clear nail polish or Permount.

#### Adhesive/Scotch Tape Preparation

- Place a clean glass slide on a sheet of white paper.
- Place a small drop of LPCB in the center of the slide.
- Touch the adhesive side of a small length of transparent tape to the surface of the colony.
- Adhere the length of the tape to the surface of the slide with LPCB.
- Observe under microscope for characteristic shape and arrangement of spores and other fungal elements.

#### Fungal Slide Mount (Fig. 2.3)

Best technique for visualization of fungal structures without disruption of arrangement.

- Take a sterile petri dish and cover it with tissue paper. Place a bent sterile glass tube or two sterile wooden sticks on the tissue paper.
- Place a sterile slide on the wooden sticks/glass tube so that it is raised above the level of the tissue paper.
- Cut a block (1x1 cm) of PDA and place it in the middle of the slide. Inoculate by stabbing all 4 sides of the block with the fungus that needs to be identified. Place a sterile coverslip on top of the block.
- Soak the tissue paper with sterile distilled water.
- Observe daily for growth and sporulation and keep the tissue soaked to ensure the environment remains moist.
- When sporulation is complete, remove coverslip from the surface of the media block, place a drop of LPCB on a fresh slide and place this coverslip on it.
- Discard the block of media from the slide, put a drop of LPCB on it and place a coverslip on top.
- Examine both slides for sporulation and arrangement of microscopic structures to identify the fungus

Fig. 2.3: Slide culture technique.



### Reading of Smear

- All smears must be read within 24 hours of preparation, at least 3 times a day: morning, noon and afternoon.
- Positive smears should be rechecked by a senior mycology technologist or consultant.
- Negative samples from sterile sites should be reviewed by a senior mycology technologist or consultant.
- For tissues with high clinical suspicion of fungal infection, prepare more than one smear especially from relatively necrotic portion before labeling it negative.

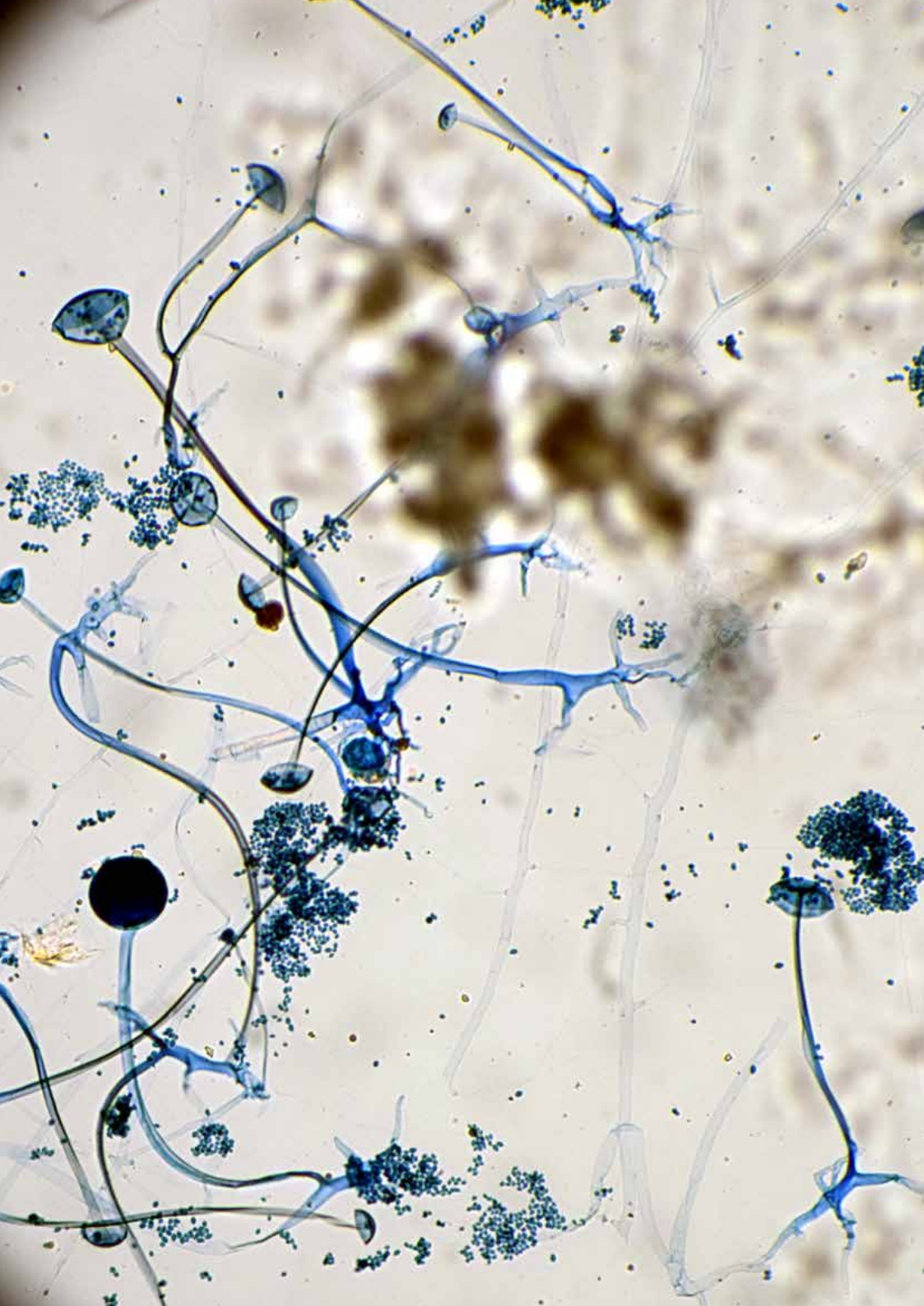
Table 2.4: Daily routine of mycology lab

<b>Step 1: Quality Control</b> <ul style="list-style-type: none"> <li>• Lab equipment</li> <li>• Media and strains</li> <li>• Light exposure</li> <li>• Temperature regulation</li> </ul>	<b>Step 2: Fungal Smears</b> <ul style="list-style-type: none"> <li>• Preparation</li> <li>• Reading schedule – 3 times a day</li> <li>• Review by senior technologist/consultant</li> </ul>
<b>Step 3: Fungal Cultures</b> <ul style="list-style-type: none"> <li>• Preparation</li> <li>• Reading schedule – daily, weekly and monthly</li> <li>• Cross-checking growth with bacterial culture sample</li> <li>• Review by senior technologist/consultant</li> </ul>	<b>Step 4: Fungal Slide Mounts</b> <ul style="list-style-type: none"> <li>• Preparation</li> <li>• Reading</li> </ul>

### Quality Control

The following measures should be taken on a daily basis to ensure QC:

- Check and record temperature readings of all incubators, refrigerators and freezers every morning.
- Log and report abnormal readings to the in-charge technologist.
- Review QC of media and strains, and record results. In case of incorrect results, take corrective action.
- Before use, physical check of plates is necessary for any signs of deterioration and contamination.
- Maintain proper inoculation conditions, temperature and pH for optimal fungal growth. Excessive heating and inappropriate pH may cause delayed growth or growth inhibition.
- Prevent prepared media from unnecessary light exposure.



# DIAGNOSIS OF FUNGAL INFECTIONS

CLINICAL LESIONS, MICROSCOPIC  
EXAMINATION AND CULTURE

# Diagnosis of Fungal Infections: Clinical Lesions, Microscopic Examination and Culture

This chapter describes common clinical presentations, growth factors, and gross culture and microscopic appearance of fungi prevalent in Pakistan. Traditionally, fungal infections were diagnosed when they manifested as superficial cutaneous infections. However, in the past few decades, a significant number of invasive infections due to haematological dissemination of fungal diseases have been diagnosed. This increase in incidence is attributable to immunocompromised states (for instance, patients suffering from haematological malignancies, undergoing chemotherapy, uncontrolled diabetes, infectious diseases such as HIV/AIDS) as well as improvements in diagnostic techniques and shortened turnaround times. Currently, antimycotics are available to manage fungal diseases but inherent resistance to antifungal therapy remains a problem for some species involved in disseminated infections.

<b>Box 3.1: Definitions</b>
Mold (mycelial form) Fungus that grows in the form of multicellular filaments called hyphae.
Yeast Fungus that grows as a single cell.
Dimorphic Fungi Fungus can exist as in both yeast and mold (mycelial) forms. Can be cultured in enriched media at 25-30°C to yield mold and at 35-37°C to yield yeast form, e.g. <i>Sporothrix schenckii</i> .

**Table 3.1: Notable identification features**

- |  |  |
|--|--|
| <ul style="list-style-type: none"> <li>• Location: intracellular or extracellular</li> <li>• Capsule: non-capsulated or encapsulated (e.g. <i>Cryptococcus</i> on India ink smear)</li> <li>• Septa: aseptate or septate</li> <li>• Septa: thin or wide</li> <li>• Hyphae: present, absent or pseudohyphae</li> <li>• Hyphae: hyaline or pigmented</li> <li>• Hyphae: acute- or wide-angled branches</li> <li>• Budding: multiple or unicellular yeasts</li> <li>• Budding: narrow or broad-based yeasts</li> <li>• Filaments: non-branching or branching (e.g. <i>Actinomyces</i> or <i>Nocardia</i>)</li> <li>• Rods: non-branching or branching (e.g. <i>Nocardia</i>)</li> </ul> | <ul style="list-style-type: none"> <li>• Arthroconidia</li> <li>• Chlamydoconidia</li> <li>• Endothrix</li> <li>• Spherules</li> <li>• Endospores</li> <li>• Sclerotic bodies</li> </ul> |
|--|--|

## Candida

Joveria Farooqi and Kauser Jabeen

*Candida* is a commensal of skin, oral and intestinal flora in humans, and disease generally results when immunity is lowered (e.g. antibiotics use, stress, diabetes) or completely compromised (e.g. HIV/AIDS). Infection can result in a spectrum of clinical presentations and some species are known to have a predilection for certain sites: *C. albicans* is the most common cause of oral and vulvovaginal candidiasis; *C. parapsilosis* is frequently reported in nail-related infections; and *C. parapsilosis* and *C. pelliculosa* are strongly associated with nosocomial infections. In recent years, the emergence of resistance has led to antifungal susceptibility testing and reporting in invasive specimens. *C. glabrata* and *C. krusei* are known for their resistance to fluconazole (the former acquired and the latter intrinsic).

### Clinical Presentation

**Table 3.2: Types of Candidiasis**

Invasive	Semi-invasive	Non-invasive
<ul style="list-style-type: none"> <li>• CNS candidiasis</li> <li>• Candida endophthalmitis</li> <li>• Candida endocarditis, pericarditis and endovascularitis</li> <li>• Intra-abdominal candidiasis</li> <li>• Candida pyelonephritis or urinary fungus ball</li> <li>• Candida osteomyelitis and arthritis</li> <li>• Candidemia</li> <li>• Chronic disseminated candidiasis</li> </ul>	<ul style="list-style-type: none"> <li>• Esophagitis</li> <li>• Chronic mucocutaneous candidiasis</li> </ul>	<ul style="list-style-type: none"> <li>• Oral thrush</li> <li>• Otitis externa</li> <li>• Cutaneous and onychomycosis</li> <li>• Chronic mucocutaneous candidiasis</li> <li>• Candiduria</li> <li>• Vulvovaginitis</li> </ul>

Oral thrush

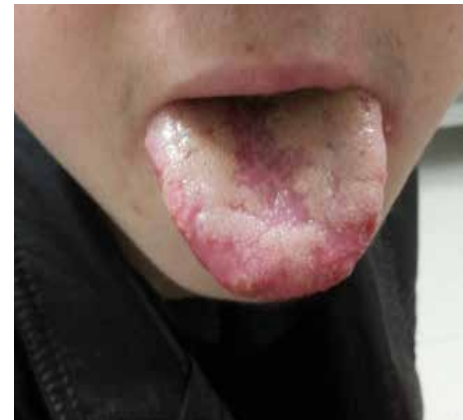

Fig. 3.1.1-1

Genital thrush (vulvovaginitis), Gram stain of vaginal swab

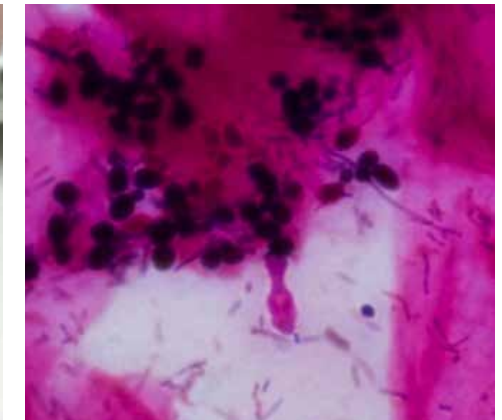


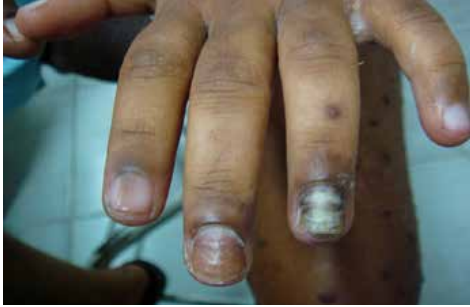Fig. 3.1.1-2

One of the commonest presentations of candidiasis. White exudate on oral mucosa due to candida overgrowth and mucocutaneous inflammation. Oral thrush is associated with extremes of ages, antibiotic therapy, chronically ill patients and is generally considered an early manifestation of disturbance in innate immunity.

Stain reveals abundant unicellular (budding yeasts) and multicellular (pseudohyphae) forms on squamous cells. *Candida* typically stains Gram positive. Genital thrush is associated with diabetes, pregnancy and compromised host immune status (recurrence common if inadequately treated). (x100)

**Onychomycosis**

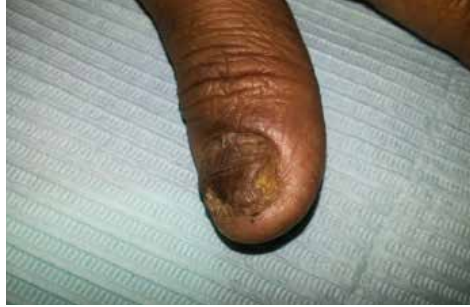**Fig. 3.1.1-3**



Thickened and discoloured nail plate with subungual hyperkeratosis and onycholysis. White adherent plaque seen in intertriginous space of ring and little fingers.

**Onychomycosis**

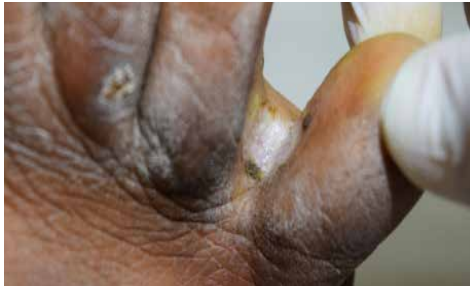**Fig. 3.1.1-4**



Discoloured and pitted nails with a crumbling nail plate. Nail folds are swollen and inflamed and show marked subungual hyperkeratosis.

**Intertrigo**

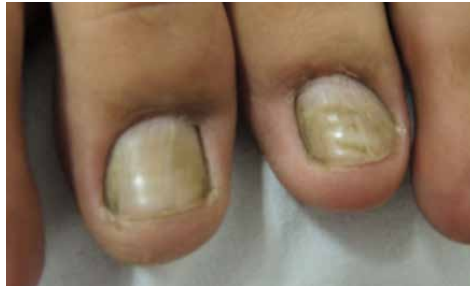**Fig. 3.1.1-5**



Itchy and at times malodorous rash typically between fourth and fifth toes due to *Candida* or dermatophyte infection. Often a feature of tinea pedis (athlete's foot).

**Chronic candidiasis**

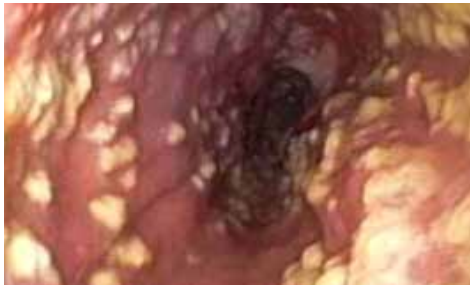**Fig. 3.1.1-6**



Recurrent candidiasis. Despite repeated antifungal therapy, the patient's nails remained discoloured and pitted after 1 year. There is no evidence of invasive disease.

**Candida esophagitis**


**Fig. 3.1.1-7**



Characterised by patches of pseudomembranous white slough along the esophageal mucosa that can be easily wiped. Frequently accompanied by oral thrush. *Candida* esophagitis is mostly seen in immunocompromised patients. Classic symptoms include dysphagia, odynophagia and weight loss due to difficulty swallowing.

**Candida otomycosis, culture on SBA**

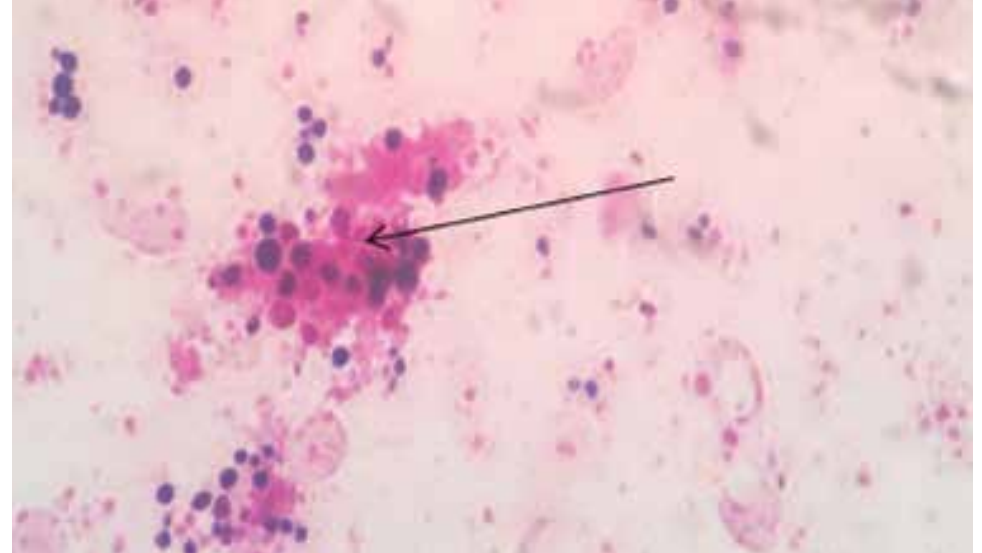
**Fig. 3.1.1-8**



Culture of external auditory canal swab on blood agar showing white yeast colonies. However, interpret ear swab cultures cautiously as *Candida* is a known skin coloniser as well as an agent of otomycosis.

**Candida endocarditis, Gram stain**

**Fig. 3.1.1-9**



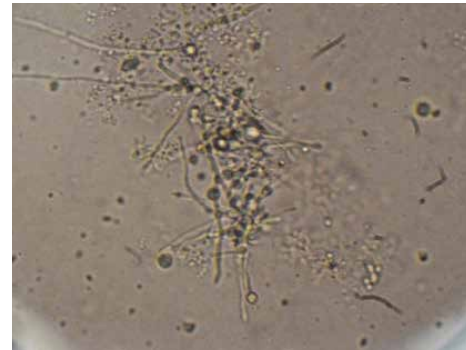
Pulmonary valve vegetation shows numerous budding yeast cells invading valve tissue. Yeast cells measure 6-8 µm in diameter. (x100)

***Candida albicans***

*C. albicans* is a dimorphic fungus that is a skin and gut commensal. Infection results in oral and vaginovaginal candidiasis in immunocompetent hosts, and fatal disseminated infections in immunocompromised patients. *C. albicans* is the most common fungal species isolated from clinical specimens. More recently, it has emerged as a cause of hospital-acquired infections, especially with implantable medical devices where it covers the surface with a biofilm.

***C. albicans*, 10% KOH smear**

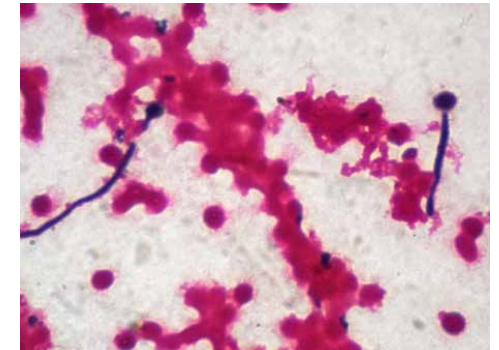
**Fig. 3.1.1-10**



Oval to subspherical budding yeasts. Presence of abundant pseudohyphae in specimen suggests overgrowth and active infection. (x40)

***C. albicans*, Gram stain from blood culture bottle**

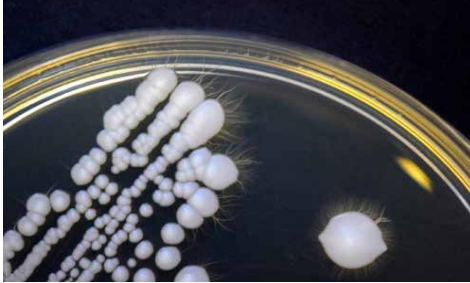**Fig. 3.1.1-11**



Sometimes *C. albicans* can give the impression of spherical yeasts. The smear should be examined in several fields before deciding on the shape and morphology of the yeast cells. (x100)

*C. albicans*, culture on SDA

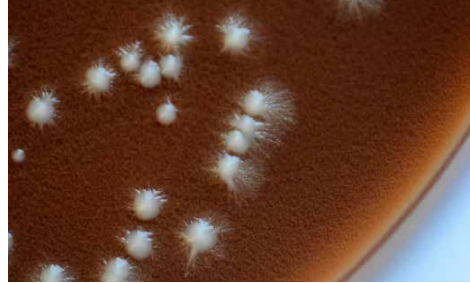Fig. 3.1.1-12



Cream coloured colonies. Small colony variants in overnight cultures give the impression of mixed growth.

*C. albicans*, culture on chocolate agar

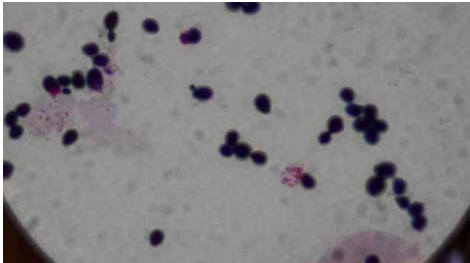
Fig. 3.1.1-13



Glistening creamy colonies sprouting mycelia or "fringes" – typical of *C. albicans*. These fringes may also rarely be seen in *C. tropicalis* colonies. Growth on chocolate agar shows even more prominent fringes or star-shaped colonies.

*C. albicans*, Gram stain

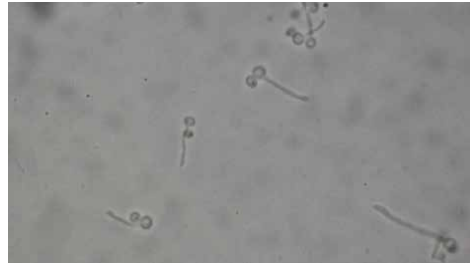Fig. 3.1.1-14



Ovoid to subspherical budding yeast cells 6-8 µm in size. (x100)

Germ tube test

Fig. 3.1.1-15



Confirmatory test to differentiate *C. albicans* from other *Candida* species. *C. albicans* produces tubular outgrowths (germ tubes or true hyphae) as opposed to elongation of a budding yeast (pseudohyphae). It is also seen in *C. dubliniensis*. (x40)

Susceptibility testing (disc diffusion, see chapter 4 for details)

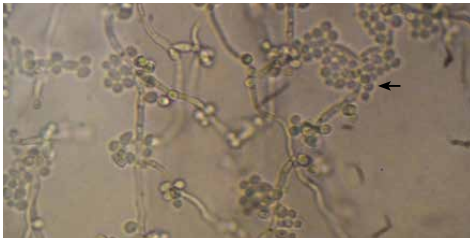
Fig. 3.1.1-17



Most strains of *C. albicans* are susceptible to triazoles, echinocandins and amphotericin. However, due to emerging resistance, especially against triazoles and echinocandins, most labs perform antifungal susceptibilities. Clinical breakpoints for zone diameters (disc diffusion) and broth microdilution are now available in both EUCAST and CLSI References.

*C. albicans*, microscopy of CMT agar

Fig. 3.1.1-16



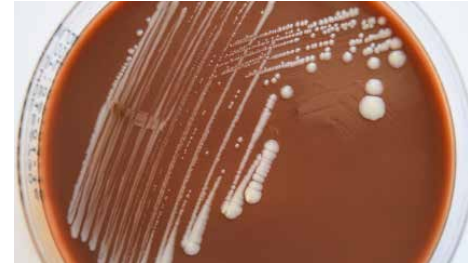On microscopy, pseudo-hyphae appear as long and slender tubules with clusters of round to oval blastoconidia (arrow). The presence of terminal double-walled round chlamydo-spores is diagnostic of *C. albicans*. These chlamydo-spores may also be seen in *C. dubliniensis* but they are usually found in clusters and are more abundant as compared to *C. albicans*. (x40)

### *Candida tropicalis*

*C. tropicalis* is part of skin and gut flora and frequently results in disseminated invasive infections in neutropenic and cancer patients.

*C. tropicalis*, culture on chocolate agar

Fig. 3.1.1-18



At 24-48 hours, small and large colony variants are seen. Smaller colonies are usually dome-shaped while the larger ones are dull white, dry and slightly elevated.

*C. tropicalis*, culture on SBA

Fig. 3.1.1-19



Similar to chocolate agar, culture in blood agar has both small and large colony variants which become less prominent after 72 hours (3 days). The colonies are initially non-haemolytic, dry and elevated but turn dome-shaped after the third day.

*C. tropicalis*, culture on SDA


Fig. 3.1.1-20



Day 4. Colonies do not glisten and are umbonated, with radial grooves around the edges only.

*C. tropicalis*, culture on BiGGY agar

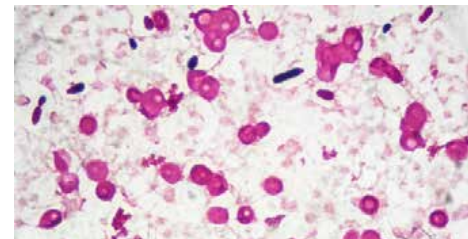
Fig. 3.1.1-21



Colonies are dry, light to dark brown, with a silver metallic sheen, most prominent on the primary streak. They are also umbonated and have radial grooves around the edges.

*C. tropicalis*, Gram stain from positive blood culture bottle

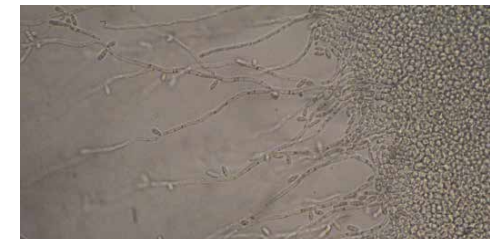Fig. 3.1.1-22



Yeast size is around 4-6 µm, almost the same size as RBCs. Shape of cells is more oval than round. Pseudo-hyphae are frequently seen on smear made from clinical specimens. (x100)

*C. tropicalis*, microscopy of CMT agar

Fig. 3.1.1-23




Long slender pseudo-hyphae with elongated blastoconidia, arising successively from older blastoconidia. This gives the appearance of a rabbit head with long ears. (x40)

**Candida parapsilosis**


*C. parapsilosis* is both a human commensal and an environmental pathogen, and is usually implicated in nail infections. It can result in a range of invasive diseases including endocarditis, endophthalmitis, meningitis and peritonitis.

*C. parapsilosis*, culture on chocolate agar Fig. 3.1.1-24



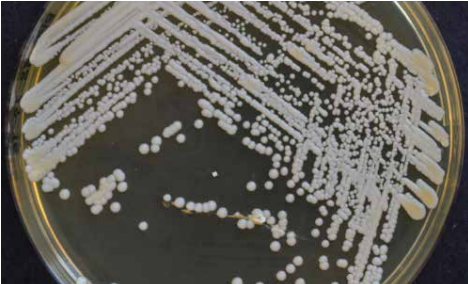
Small cream-coloured dome-shaped glistening colonies appear after 48 hours of incubation.

*C. parapsilosis*, culture on SBA Fig. 3.1.1-25



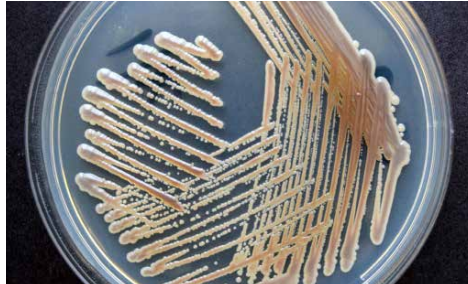
Colonies are non-haemolytic dome-shaped glistening later curling up and becoming lacy. Prominent after 48 hours.

*C. parapsilosis*, culture on SDA Fig. 3.1.1-26



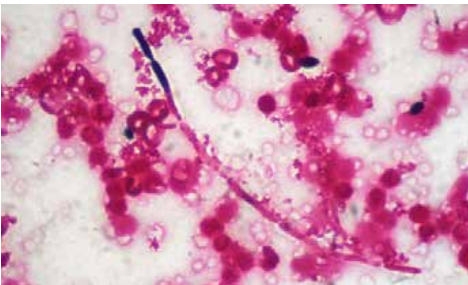
Colonies are small and glistening at 48 hours but later wrinkle and appear lacy.

*C. parapsilosis*, culture on BiGGY agar Fig. 3.1.1-27



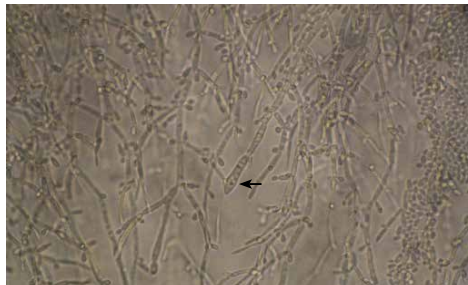
Colonies are light brown with a purple or lilac tinge, sometimes bordering on grey. Later, colonies curl and become lacy.

*C. parapsilosis*, Gram stain from blood culture Fig. 3.1.1-28



Yeasts are oval and 4-6 µm in diameter, approximately the same size as red blood cells. Pseudohyphae are less common in clinical specimens. (x100)

*C. parapsilosis*, microscopy of CMT agar Fig. 3.1.1-29



Short slender delicate pseudohyphae with elongated blastoconidia, more tapered than *C. tropicalis*. Some swell up to form giant (balloon) cells (arrow). (x40)

**Candida glabrata**

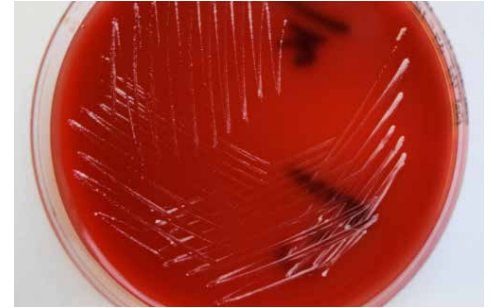
*C. glabrata* is both a commensal and environmental pathogen. It can cause mucosal surface infections (oropharyngeal, esophageal, and vaginal candidiasis) and is now increasingly isolated in disseminated fungemia.

*C. glabrata*, culture on chocolate agar Fig. 3.1.1-30



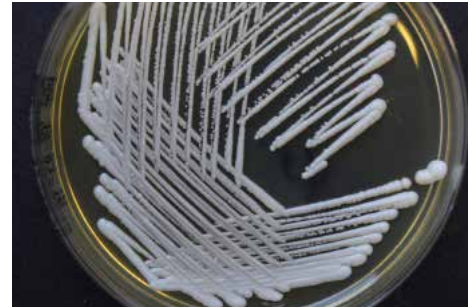
Tiny white glistening colonies appear at 48 hours. Texture is not creamy, more like bacteria.

*C. glabrata*, culture on SBA Fig. 3.1.1-31



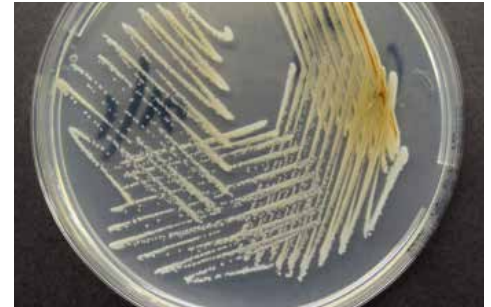
Similar to chocolate agar, tiny white non-haemolytic colonies.

*C. glabrata*, culture on SDA Fig. 3.1.1-32



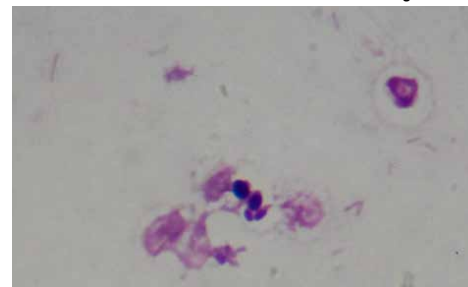
Colonies are small, glistening at 48 hours but older colonies wrinkle up and appear lacy.

*C. glabrata*, culture on BiGGY agar Fig. 3.1.1-33



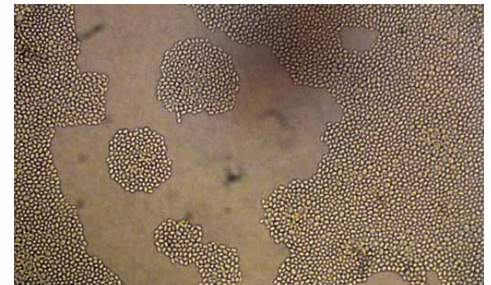
Colonies appear off-white.

*C. glabrata*, Gram stain from positive blood culture bottle Fig. 3.1.1-34



Yeasts are oval and smaller than red blood cells, approximately 2-4 µm in diameter. Pseudohyphae are never seen. (x100)

*C. glabrata*, microscopy of CMT agar Fig. 3.1.1-35



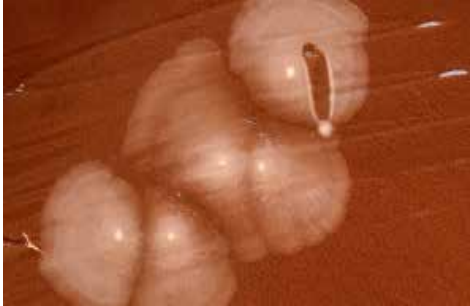Yeast cells are small and oval. Pseudohyphae absent. (x10)

*Candida krusei*

*C. krusei* results in nosocomial disseminated infections in patients with haematological malignancies or in immunosuppressed states.

*C. krusei*, culture on chocolate agar

Fig. 3.1.1-36



Colonies are large flat, dry and grey. They resemble the large spreading colonies of *bacillus*.

*C. krusei*, culture on SDA

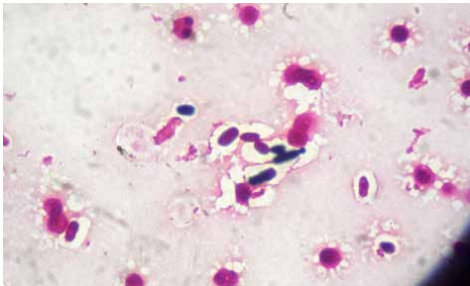
Fig. 3.1.1-38



Colonies are dry, almond-shaped and spreading across the plate.

*C. krusei*, Gram stain on positive blood culture sample

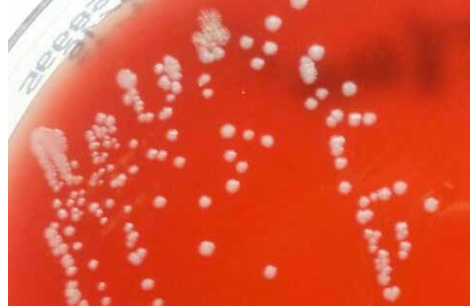Fig. 3.1.1-40



Yeast form is 4-6 µm, almost the same size as RBCs. Shape of cells is oval to elliptical. Pseudohyphae may be seen. (x100)

*C. krusei*, culture on SBA

Fig. 3.1.1-37



Non-haemolytic flat, dry colonies, spreading over the agar surface.

*C. krusei*, culture on BiGGY agar

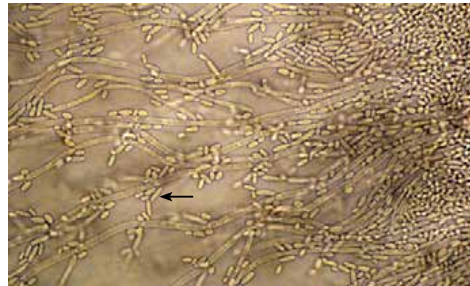
Fig. 3.1.1-39



Colonies are dark brown with a brown diffusible pigment and a silver metallic sheen.

*C. krusei*, microscopy of CMT agar

Fig. 3.1.1-41



Long slender pseudohyphae with elongated blastoconidia, aligned both parallel and perpendicular to the axis of the pseudohyphae, giving a cross-matchstick arrangement (arrow). (x40)

*Candida lusitanae*

*C. lusitanae* is a gut commensal that is a very rare cause of invasive infections in patients with prolonged neutropenia, bone marrow transplantation or on high-dose cytoreductive chemotherapy.

*C. lusitanae*, culture on chocolate agar

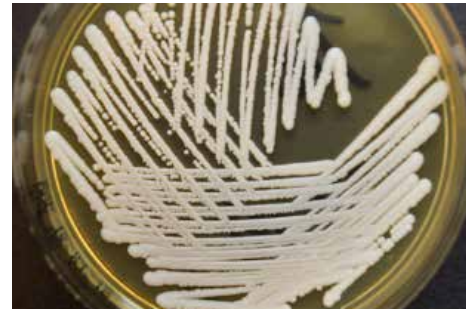Fig. 3.1.1-42



Small white glistening dome-shaped colonies.

*C. lusitanae*, culture on SDA

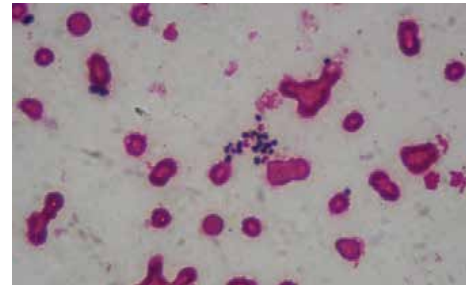
Fig. 3.1.1-44



White glistening dome-shaped colonies.

*C. lusitanae*, Gram stain

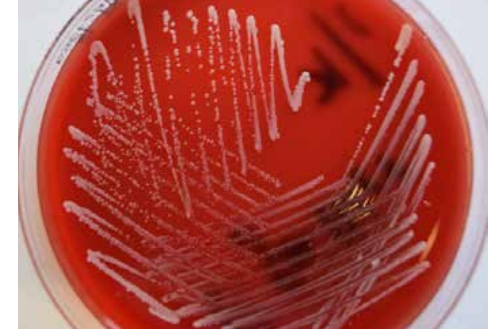
Fig. 3.1.1-46



Small oval budding yeast cells, 2-4 µm in size. Most do not form pseudohyphae in specimen. (x100)

*C. lusitanae*, culture on SBA

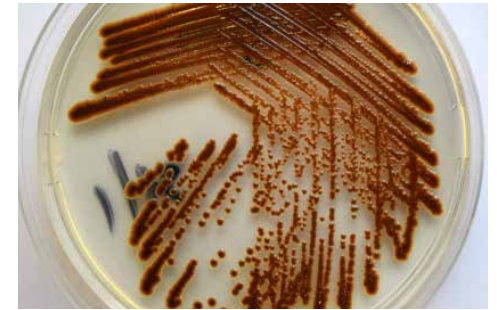
Fig. 3.1.1-43



Similar to chocolate agar, the colonies are white, small, glistening and dome-shaped. Like most yeasts, colonies are non-haemolytic.

*C. lusitanae*, culture on SDA

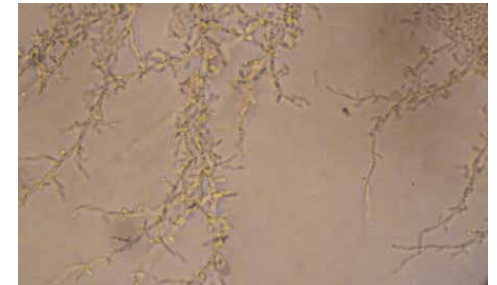
Fig. 3.1.1-45



Uniformly coloured dark brown glistening colonies giving the impression of tempered chocolate.

*C. lusitanae*, microscopy of CMT agar

Fig. 3.1.1-47

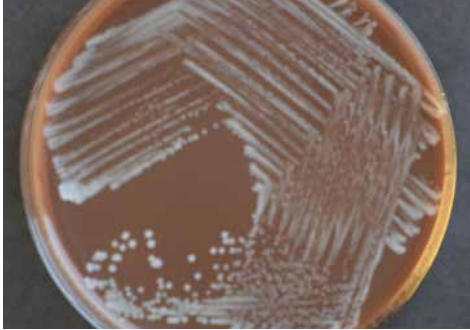


Short curved, branched pseudohyphae, with elongated blastoconidia. (x40)

*Candida guilliermondii*

*C. guilliermondii* is an uncommon skin commensal as well as an environmental pathogen that is associated with onychomycosis and superficial cutaneous infections. Rarely seen as a cause of invasive fungal infection.

*C. guilliermondii*, culture on chocolate agar Fig. 3.1.1-48



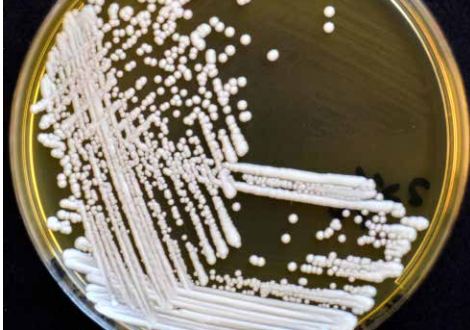Colony morphology is quite similar to *C. lusitanae*. Small white glistening dome-shaped colonies.

*C. guilliermondii*, culture on SBA Fig. 3.1.1-49



Growth similar to chocolate agar. Small white glistening dome-shaped non-haemolytic colonies.

*C. guilliermondii*, culture on SDA Fig. 3.1.1-50



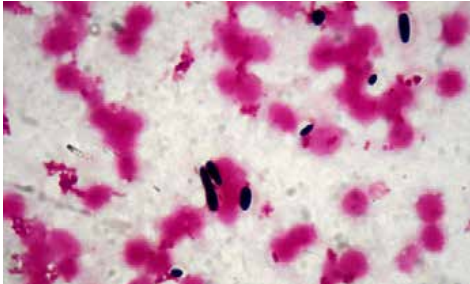
Small white glistening dome-shaped colonies.

*C. guilliermondii*, culture on BiGGY agar Fig. 3.1.1-51



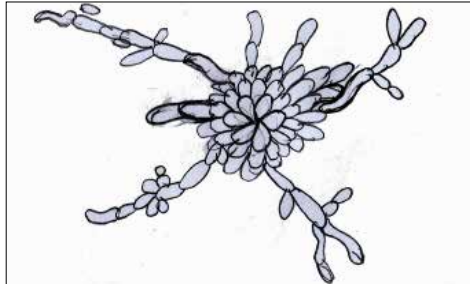
Uniformly coloured brown glistening colonies.

*C. guilliermondii*, Gram stain Fig. 3.1.1-52



Small budding yeast cells oval to elliptical in shape. Pseudohyphae usually not seen in clinical specimens. (x100)

*C. guilliermondii*, microscopy of CMT agar Fig. 3.1.1-53




Small clusters of blastoconidia giving rise to short pseudohyphae. Yeast cells are oval to elliptical and 2-3 µm in size. (x40)

*Candida auris*

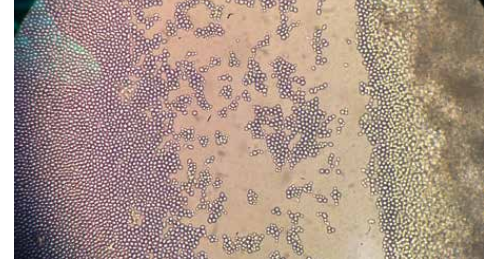
*C. auris* has recently emerged across the globe as a nosocomial pathogenic *Candida* species closely related to *Candida haemulonii*. It was first identified as a separate species in a report from South Korea in 2008, and there have been reports of outbreaks in Pakistan, Venezuela, South Africa and United Kingdom. The most alarming feature of this organism is the ability to develop multi-drug resistance, that is, resistance against two or more classes of antifungal agents, including amphotericin. Due to resistance to various group of antifungal drugs, morbidity and mortality is higher than other *Candida* infections.

*C. auris*, culture on SBA Fig. 3.1.1-54



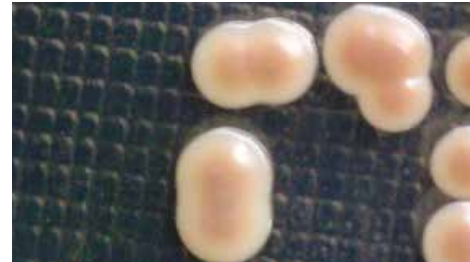Small white dome-shaped non-haemolytic colonies with a butyrous texture.

*C. auris*, microscopy of CMT agar Fig. 3.1.1-55



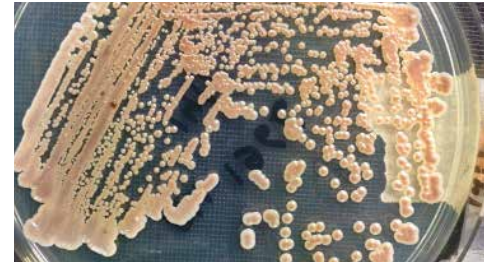Microscopically, the cells are small to medium sized oval budding yeasts not forming any pseudohyphae. (x40)

*C. auris*, culture on BiGGY agar Fig. 3.1.1-56




Close-up view shows small to medium sized yeasts.

*C. auris*, culture on BiGGY agar Fig. 3.1.1-57



Light brown coloured colonies with a white margin.

Susceptibility testing Fig. 3.1.1-58



Disc diffusion method. *C. auris* is considered inherently resistant to fluconazole (arrow) and is known to acquire resistance against several antifungal classes, including amphotericin and echinocandins.

## Cryptococcus neoformans

Kauser Jabeen and Joveria Farooqi

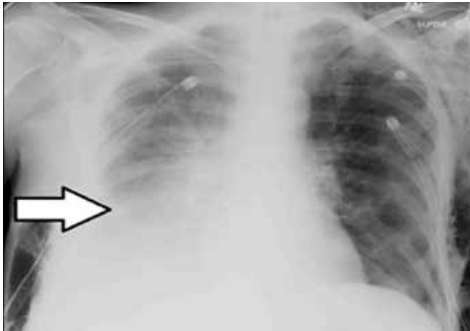
*C. neoformans* is an environmental yeast causing pulmonary, CNS and skin lesions. The most common site of entry is lungs where it can cause asymptomatic infection and even life-threatening pneumonia. Serum cryptococcal antigen detection test is performed to rule out invasive cryptococcosis.

It is an important pathogen in morbidities associated with HIV/AIDS and CNS involvement should be ruled out in patients at high risk of dissemination. Focus can persist in prostate after therapy for systemic disease and may act as a reservoir for relapse in men with AIDS.

### Clinical Presentation

#### Pulmonary cryptococcosis

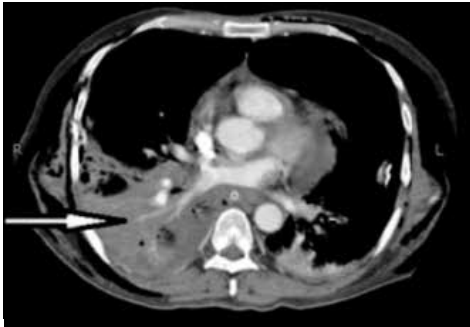
Fig. 3.1.2-1



Chest radiograph shows complete opacification of the right lower lobe.

#### Pulmonary cryptococcosis

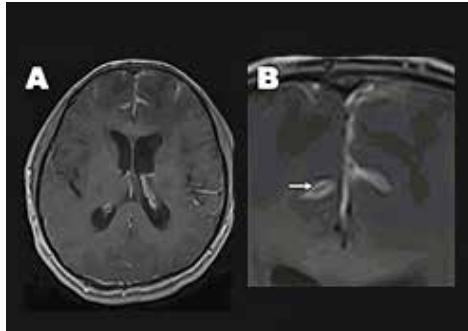
Fig. 3.1.2-3



CT scan shows consolidation (arrow) in the right lower lobe.

#### Cryptococcal meningitis. A (post-contrast) and B (magnified)

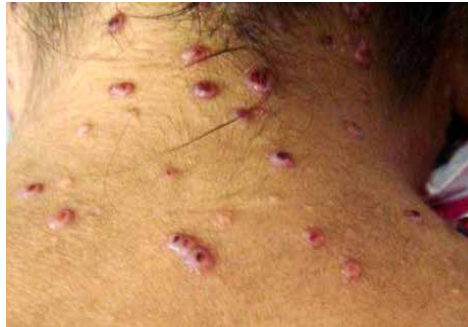Fig. 3.1.2-2



Axial T1-weighted scans show nodular meningeal enhancement with micro-abscesses. There is hydrocephalus. CSF examination was positive for *Cryptococcus* spp.

#### Cutaneous cryptococcosis

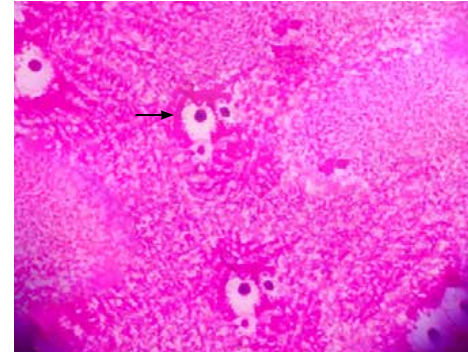
Fig. 3.1.2-4



Common presentations of cutaneous cryptococcosis include papules, maculopapules, ulcers and cellulitis. In severely immunosuppressed patients, skin manifestations may reflect disseminated cryptococcal disease.

#### *C. neoformans*, Gram stain of cerebrospinal fluid

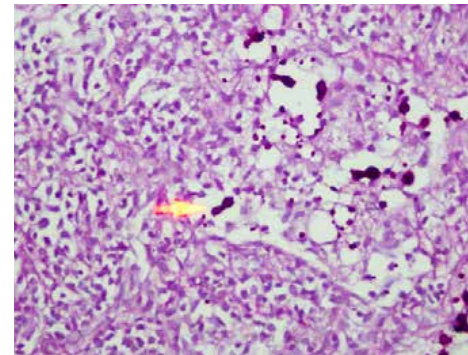
Fig. 3.1.2-5



Round budding yeasts with narrow-based budding with capsule. (x100)

#### *C. neoformans*, PAS stain of lung tissue

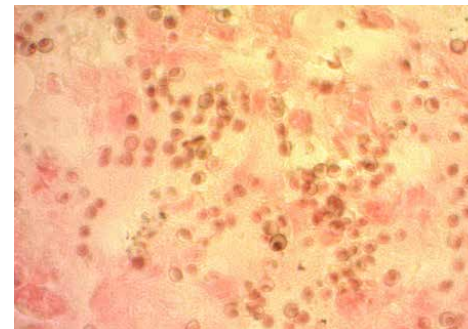
Fig. 3.1.2-7



Dark pink round budding yeast cells with surrounding capsular artefact. (x40)

#### *C. neoformans*, Fontana-Masson stain of skin biopsy


Fig. 3.1.2-9



Cryptococcal cells are stained dark brown to black. (x40)

#### *C. neoformans*, India ink preparation

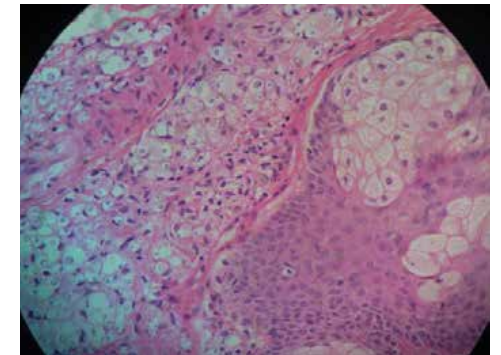
Fig. 3.1.2-6



Round budding cells with halo due to capsule. (x40)

#### *C. neoformans*, PAS stain of skin biopsy

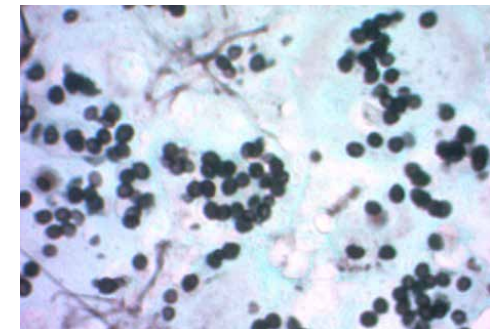
Fig. 3.1.2-8



Spherical yeast cells with narrow-based budding. Thick capsule at times does not allow strong staining of yeast cells. (x40)

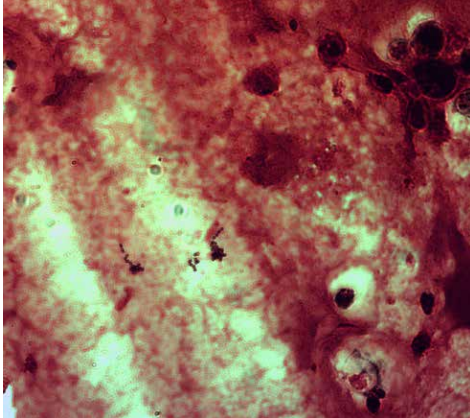
#### *C. neoformans*, Gomori methanamine silver nitrate stain of skin biopsy

Fig. 3.1.2-10



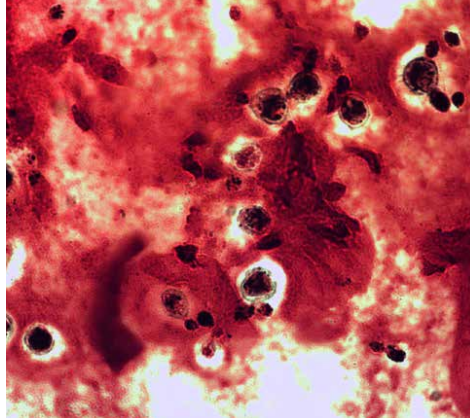
Round black budding yeast cells. (x40)

*C. neoformans*, Gram stain of sputum sample Fig. 3.1.2-11

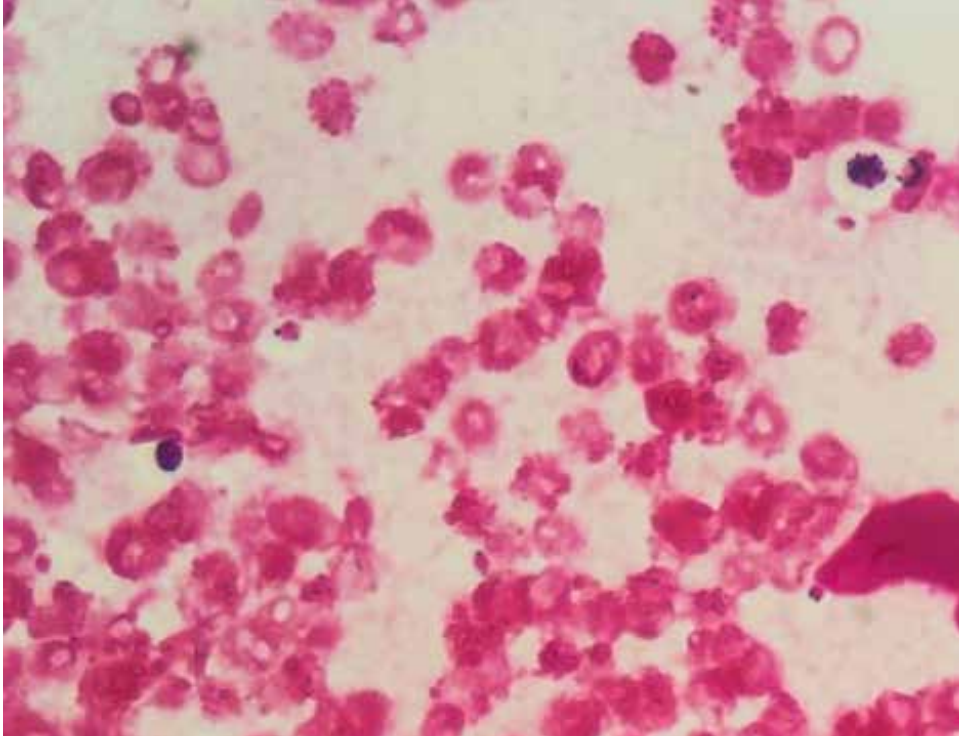


Round budding yeasts (5-7 µm in size) without pseudohyphae with some cells exhibiting multipolar budding. (x100)

Multipolar budding Fig. 3.1.2-12

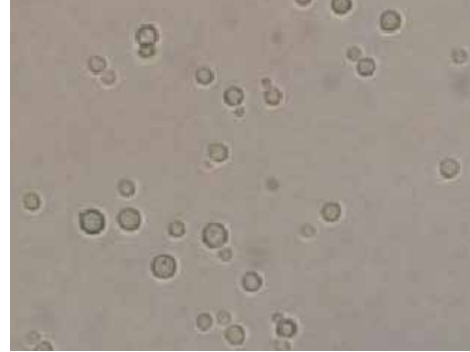

*C. neoformans*, Gram stain of smear prepared from positive blood culture Fig. 3.1.2-13



Round budding yeasts without pseudohyphae. *Cryptococcus* typically stains gram positive and may be mistaken for a lymphocyte. India ink smear should be performed for diagnosis. (x100)

*C. neoformans*, wet mount preparation Fig. 3.1.2-14



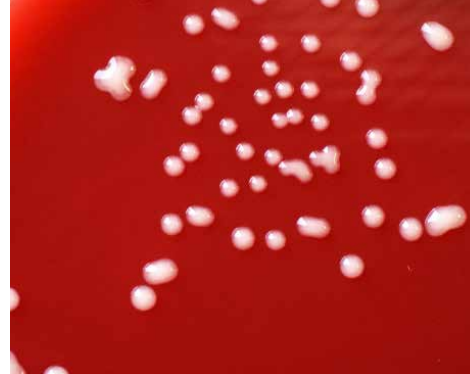Ovoid to subspherical budding yeast cells. (x40)

*C. neoformans*, Gram stain Fig. 3.1.2-15




Ovoid to subspherical budding yeast cells. (x100)

*C. neoformans*, culture on SBA Fig. 3.1.2-16



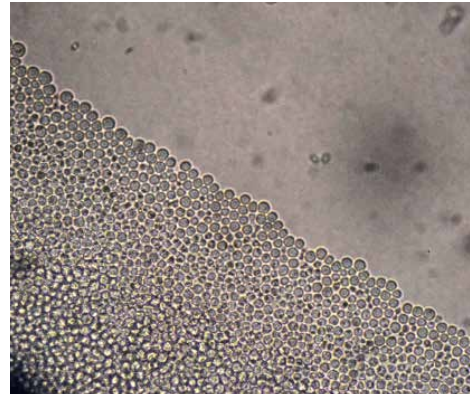
Mucoid colonies due to presence of capsule.

*C. neoformans*, culture on SDA Fig. 3.1.2-17



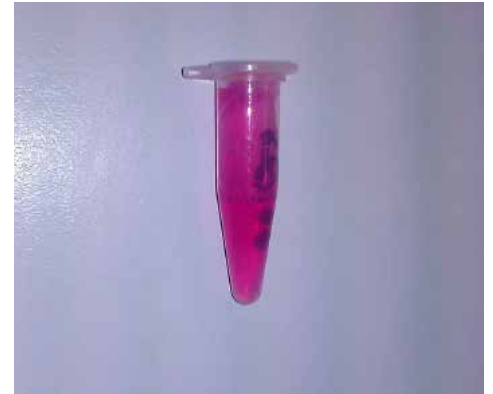Mucoid colonies due to presence of capsule.

*C. neoformans*, microscopy of CMT agar Fig. 3.1.2-18



Clusters of round blastospores. (x10)

Urea test Fig. 3.1.2-19



Most *Cryptococcus* strains are urease positive.

## Rare Yeasts

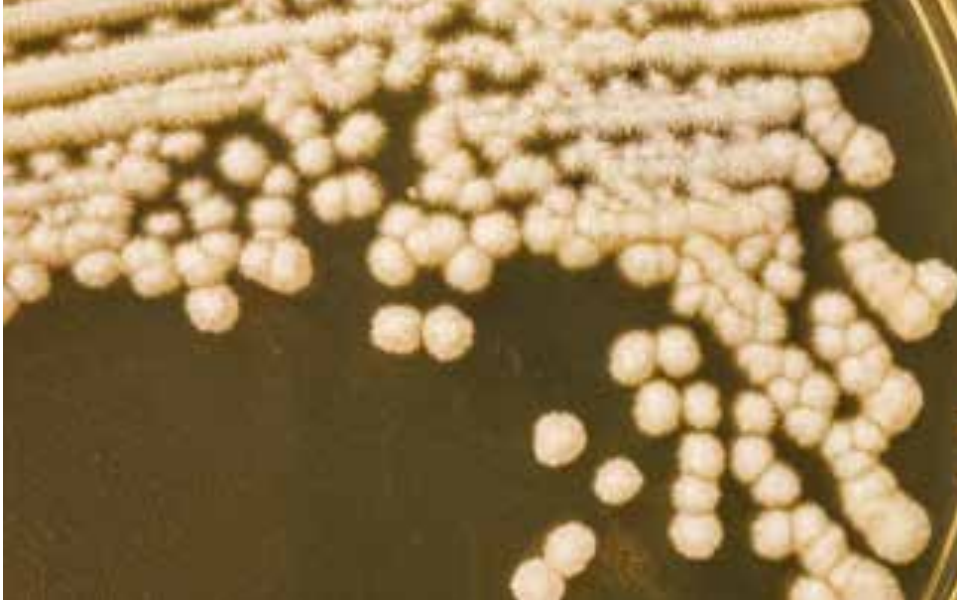Kausar Jabeen and Joveria Farooqi

### *Geotrichum* species

*Geotrichum* is an environmental organism and part of normal flora in humans, and results in disseminated infection in immunosuppressed patients.

*Geotrichum* spp., culture on SDA agar

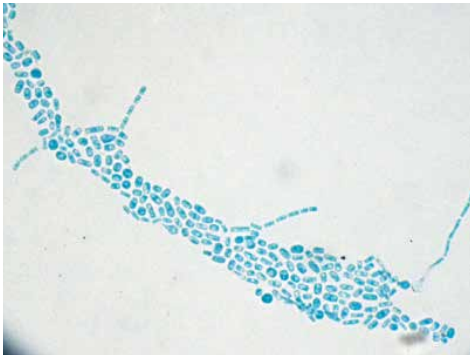Fig. 3.1.3-1



Colonies are initially yeast-like but later become dry with development of low aerial mycelia.

*Geotrichum* spp., photomicrographs of slide culture

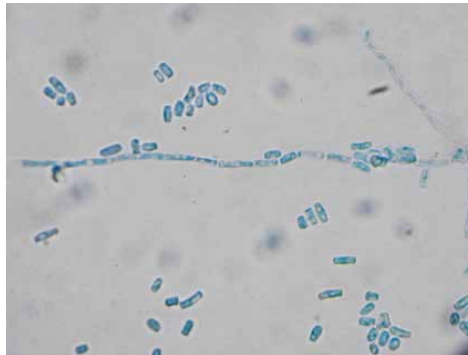
Fig. 3.1.3-2



True hyphae giving lateral branches at right angle. These lateral branches break into rectangular arthroconidia of variable lengths. There are no blastoconidia. Most strains are urease negative. (x10)

Arthroconidia breaking off from hyphae, absence of blastoconidia

Fig. 3.1.3-3

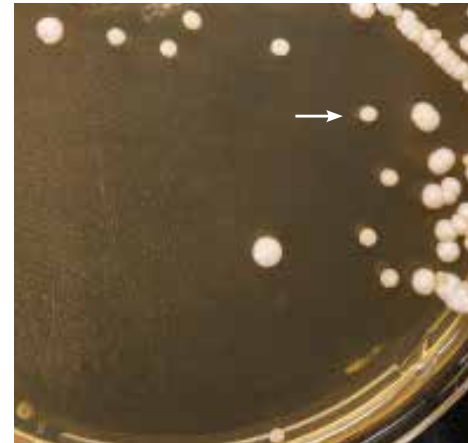


### *Trichosporon* species

*Trichosporon* is a skin commensal that results in superficial skin, hair (white piedra) and nail infection. It is the second common cause of life-threatening disseminated yeast infections.

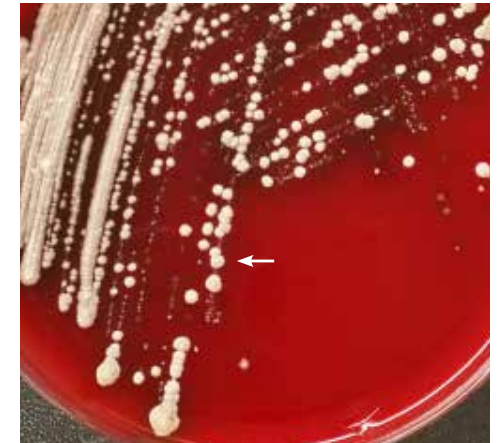*Trichosporon* spp., culture on SDA agar

Fig. 3.1.3-4



*Trichosporon* spp., culture on SBA agar

Fig. 3.1.3-5



Growth of moist and yeast-like colonies that later become dried up with wrinkled heaps at the centre of the plate (arrow) in contrast with smooth colonies of *Candida*.

Dry wrinkled chalky white colonies (arrow).

*Trichosporon* spp., microscopy of CMT agar

Fig. 3.1.3-6



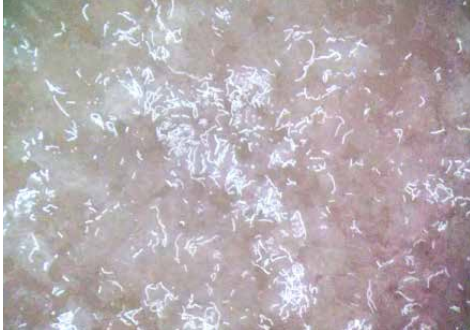True hyphae and pseudohyphae. These hyphae fragment into arthroconidia. Blastoconidia along the hyphae may be seen and helps in differentiation of *Trichosporon* from *Geotrichum* species. Most strains are urease positive. (x100)

*Malassezia furfur*

*M. furfur* is a skin commensal in sebaceous-rich areas of the body, and causes dandruff, seborrheic dermatitis and tinea versicolor. It is also a known cause of sepsis in neonates receiving parenteral nutrition with lipid-rich supplements. The growth of *Malassezia* species (with an exception of *Malassezia pachydermatis*) requires fatty acid and therefore this yeast does not grow on routine fungal culture media.

Tinea versicolor, microscopic examination –

Calcofluor white stain (fluorescent) of skin scrapings Fig. 3.1.3.7



Skin scrapings from patient with tinea versicolor reveals both yeast and hyphal form – classical “spaghetti and meatball appearance”. (x40)

*M. furfur*, culture on SDA agar with olive oil overlay Fig. 3.1.3.8



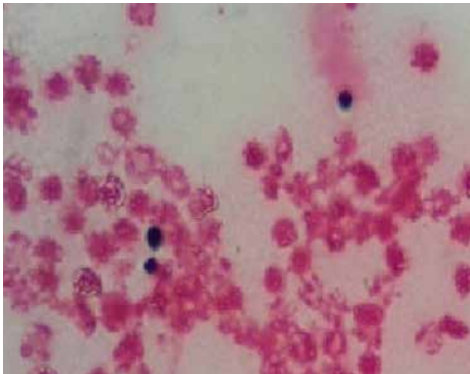
Growth of *M. furfur* requires fatty acid and in laboratory fungal growth media is overlaid with olive oil to promote growth as shown in the image. Colonies of *M. furfur* are smooth and yeast-like that later become dry and wrinkled. Microscopy of these colonies reveals yeast cells with distinct collarettes.

*Rhodotorula* species

*Rhodotorula* is an environmental yeast, known for its distinctive red pigmentation. It results in invasive infections in hospitalised patients with hematological malignancies, AIDS, burns, central venous line insertion as well as IV drug abusers and patients admitted in the ICU.

*Rhodotorula* spp., Gram stain from a positive blood culture bottle

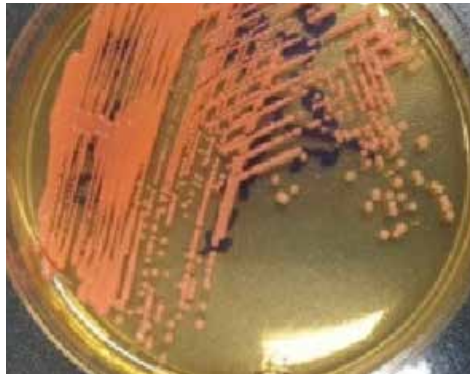Fig. 3.1.3.9



Oval budding yeast cells with capsular artefact. Presence of capsule may be mistaken as *Cryptococcus* species. (x100)

*Rhodotorula* spp., culture on SDA

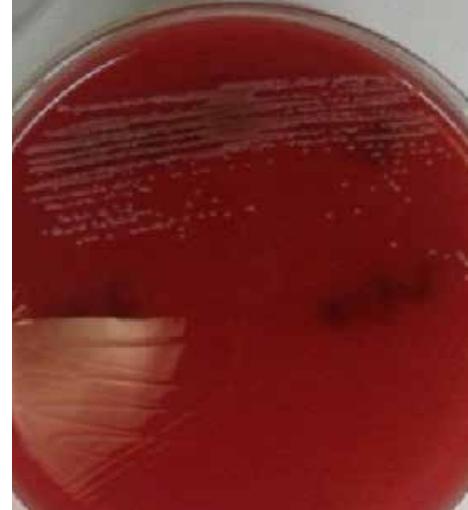
Fig. 3.1.3.10



Colonies grow rapidly and mature in 4 days. Colour of colonies is red, reddish orange or pink. Colonies may become mucoid due to presence of capsule.

*Rhodotorula* spp., culture on SBA

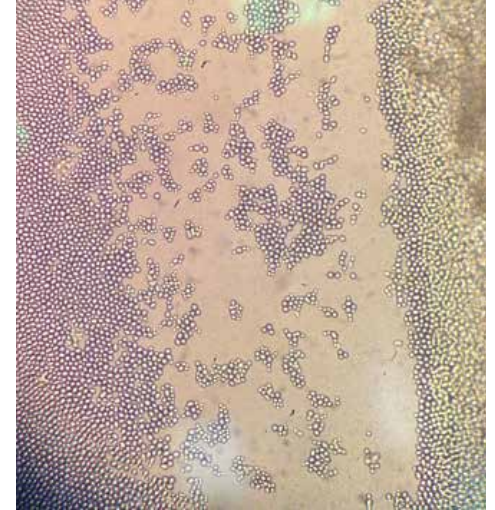
Fig. 3.1.3-11



Colonies grow rapidly and mature in 4 days. Colour of colonies is red, reddish orange or pink. Colonies may become mucoid due to presence of capsule.

*Rhodotorula* spp., microscopy of CMT agar

Fig. 3.1.3-12



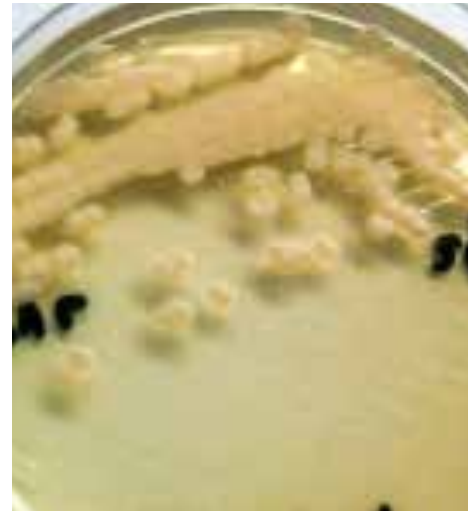Oval-elongated cells that produce rudimentary pseudohyphae. These are urease positive and usually grow at 37°C. (x10)

*Ustilago (Pseudozyma) species*

*Ustilago* is a plant pathogen that is rarely associated with human disease, however, it can cause blood stream infections in neonates and immunosuppressed patients.

*Ustilago* spp., culture on SDA

Fig. 3.1.3-13



Initial white, yeast-like colonies that later become raised and membranous.

*Ustilago* spp., wet preparation of colony

Fig. 3.1.3-14



Irregular, elongated, spindle-shaped cells.

## Aspergillus

Afia Zafar

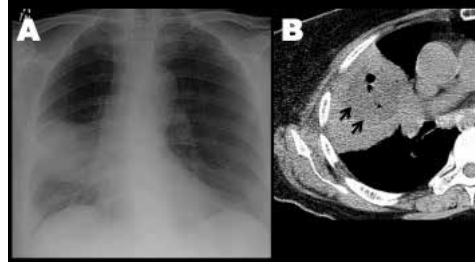
Over 200 different molds are classified under this species. Found in oxygen-rich and saccharide-rich environments, such as on post-harvest crops storage. Aspergillosis includes wide range of clinical diseases, which ranges from invasive infections to simple allergies. The most serious form of disease is invasive pulmonary Aspergillosis which occurs in immunocompromised hosts and sometime disseminates to other organs. *Aspergillus fumigatus* is the most frequent pathogenic *Aspergillus* globally but in Pakistan, *A. flavus* causes most of invasive infections followed by *A. fumigatus*, *A. terreus* and *A. niger*. For clinical laboratories, identification of *Aspergillus* up to species level is crucial as variable susceptibilities to antifungal drugs influence the selection of a drug to be used for the management of a case. Fungal hyphae are angioinvasive and lead to the formation of mycotic emboli, hemorrhages and infarction of tissue.

### Clinical Presentation

**Table 3.3: Types of Aspergillosis**

Hypersensitivity	Colonisation	Superficial	Invasive
<ul style="list-style-type: none"> <li>Allergic bronchopulmonary aspergillosis (ABPA)</li> <li>Asthma</li> <li>Allergic rhinosinusitis</li> </ul>	<ul style="list-style-type: none"> <li>Aspergilloma</li> </ul>	<ul style="list-style-type: none"> <li>Keratitis</li> <li>Otomycosis</li> <li>Sinusitis</li> <li>Cutaneous</li> </ul>	<ul style="list-style-type: none"> <li>Pulmonary                             <ul style="list-style-type: none"> <li>Aspergillosis (acute and chronic)</li> </ul> </li> <li>Tracheobronchitis</li> <li>Extrapulmonary                             <ul style="list-style-type: none"> <li>CNS</li> <li>Endophthalmitis</li> <li>Endocarditis</li> <li>Osteomyelitis and arthritis</li> </ul> </li> </ul>

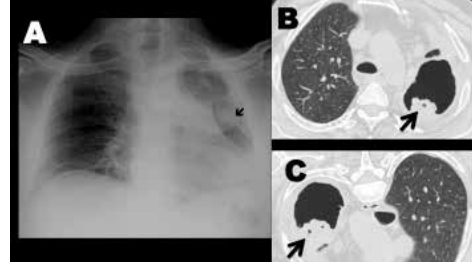
**Invasive pulmonary aspergillosis Fig. 3.2-1**



**A.** Postero-anterior radiograph of 56-year-old female patient shows right middle lobe pneumonia, diffuse infiltrates in both lungs and halo sign.

**B.** Non-enhanced CT scan shows the centre of the consolidated lesion liquefying to turn into a thick-walled abscess (arrows). *Aspergillus* spp. was isolated from the pus aspirate.

**Aspergilloma Fig. 3.2-2**

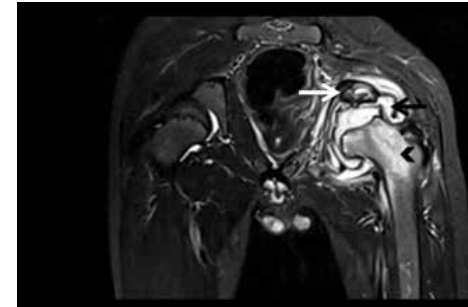


Middle-aged male patient with recurrent haemoptysis.

**A.** Postero-anterior radiograph shows a well-defined spherical thin-walled cavity in the left middle zone (arrow). Note clear “halo” around the opacity.

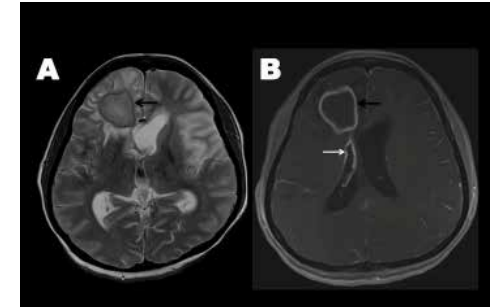
**B (supine) and C (prone).** Non-contrast CT chest in lung window settings. Free-lying soft tissue density ball in a cavity which changes position with gravity (arrow). Appearance consistent with aspergilloma (fungal ball) that occurs when inhaled conidia enter a pre-existing cavity in lung and germinate to form a solid ball of fungal mycelium. Rarely can lead to invasive disease.

**Fungal arthritis and osteomyelitis Fig. 3.2-3**



A 10-year-old boy presented with history of painful swollen left hip and an inability to walk. Coronal inversion recovery (STIR) MR of both hips shows marrow edema involving the acetabulum and the proximal femur (arrow head), joint effusion (white arrow) and an intraosseous abscess in the roof of the acetabulum (black arrow). Compare with the normal right hip. Joint aspirate revealed growth of *Aspergillus* spp.

**Brain abscess Fig. 3.2-4**

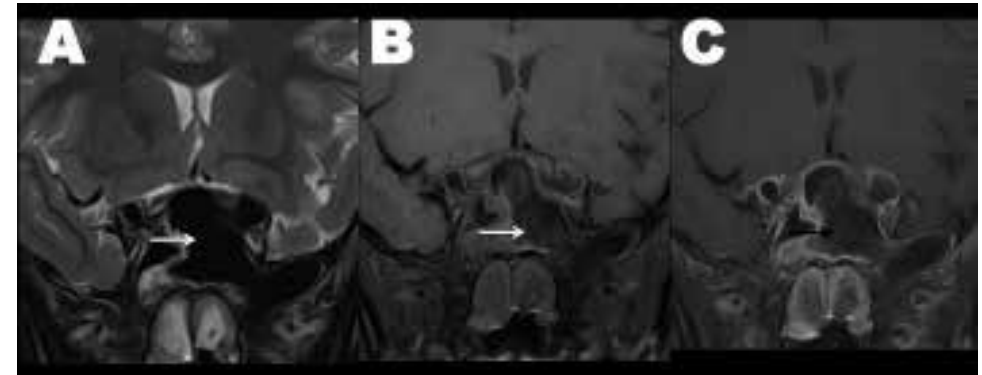


A 26-year-old female patient presented with headache and drowsiness.

**A.** Axial T2-weighted MRI of brain shows a well-defined low T2-signal lesion in the right frontal lobe with surrounding edema (arrow).

**B.** Axial contrast-enhanced T1-weighted MRI of brain shows marked peripheral enhancement (black arrow) as well as involvement of the left lateral ventricular lining (white arrow). Radiological findings are consistent with diagnosis of brain abscess with ventriculitis. Similar presentation with tuberculous infection. Both the CSF as well as the aspirate from the abscess had growth of *Aspergillus* spp.

**Fungal sinusitis extending into intracranial space Fig. 3.2-5**



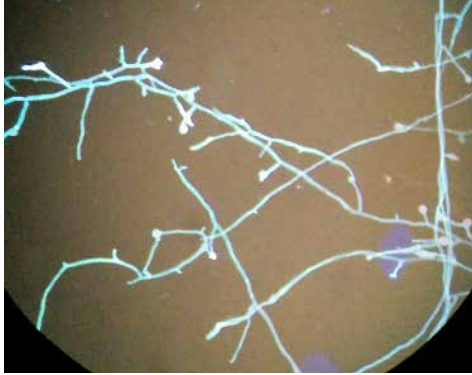
A 14-year-old boy with no known co-morbid presented with complaints of reduced vision in left eye and headaches.

**A.** Coronal T2-weighted MRI scan shows an expanded sphenoid sinus bulging into the intracranial space. The sinus is filled with material which is profoundly low-signal on T2-weighted image resembling air (arrow).

**B (pre-contrast) and C (post-contrast).** Coronal T1-weighted scans shows intermediate signal from the mass (white arrow) with some enhancement (black arrow). This combination of a profoundly low signal on T2-weighted scan and intermediate signal on T1-weighted scan with enhancement is pathognomonic of fungal sinusitis secondary to an *Aspergillus* infection. Fungal sinusitis can be fatal and is mostly seen in tropical countries.

Keratitis, Calcofluor white stain

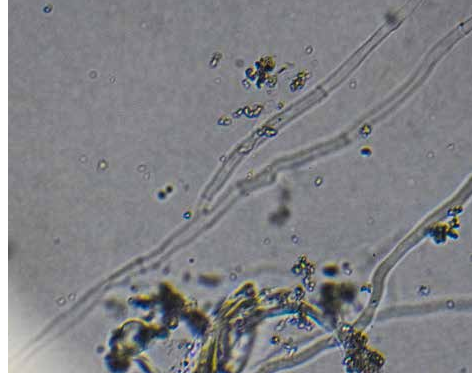
Fig. 3.2-6



Corneal ulcer scraping shows hyphae. *Aspergillus*, mainly *A. fumigatus*, is an infrequent cause of infection of the cornea after trauma or corneal surgery. (x20)

*A. fumigatus*, 10% KOH wet mount smear

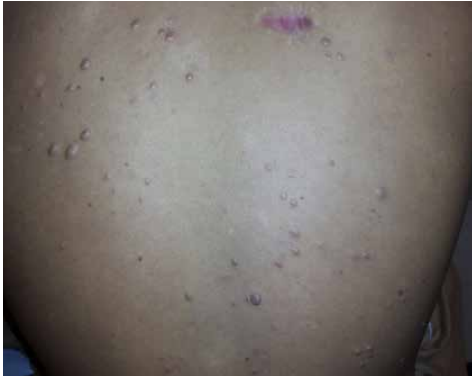Fig. 3.2-7



Septate hyphae seen in sputum. (x40)

Cutaneous aspergillosis

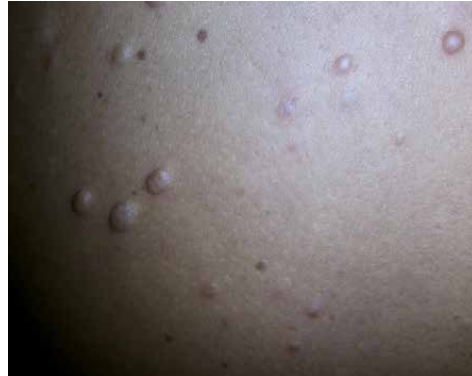Fig. 3.2-8



A 32-year-old male patient presented with a 6-month history of asymptomatic flesh-coloured papules on trunk gradually increasing in number.

Cutaneous aspergillosis, close-up of skin papules

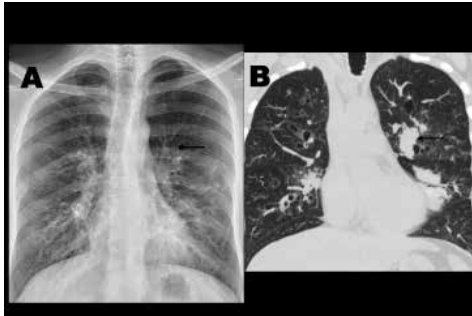
Fig. 3.2-9



Culture shows growth of *Aspergillus* spp. Patient responded to treatment with itraconazole but was lost to follow-up.

Allergic bronchopulmonary aspergillosis (ABPA)

Fig. 3.2-10



A 25-year-old female patient known asthmatic presented with an episode of haemoptysis.

**A.** Postero-anterior radiograph of chest shows central bronchiectasis with a dilated fluid-filled bronchus at the left hilum.

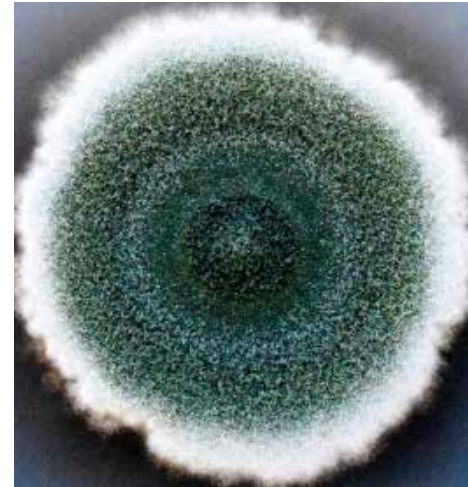
**B.** Coronal reformatted non-contrast CT of the chest better delineates the extent of the central bronchiectasis and the fluid-filled bronchus. Appearances consistent with ABPA.

### *Aspergillus fumigatus*

The most commonly isolated *Aspergillus* species typically found in soil and compost. *A. fumigatus* mold cause fatal acute pulmonary infection as well as chronic pulmonary infections and allergic bronchopulmonary aspergillosis. It is also the most common cause of invasive fungal infection in immunosuppressed individuals.

*A. fumigatus*, front view of culture on SDA

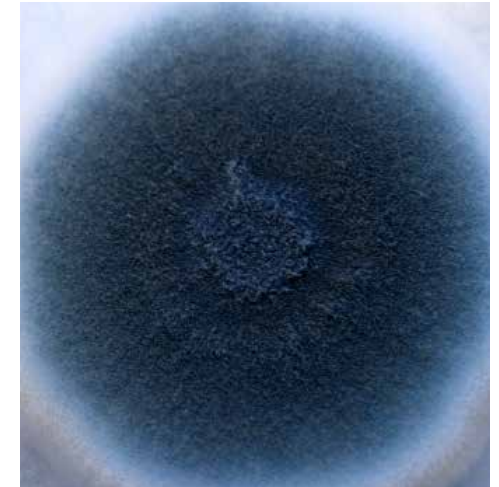
Fig. 3.2-11



Day 3, incubation at 37°C. Smoky grey-green and velvety-powdery growth.

*A. fumigatus*, front view of culture on PDA

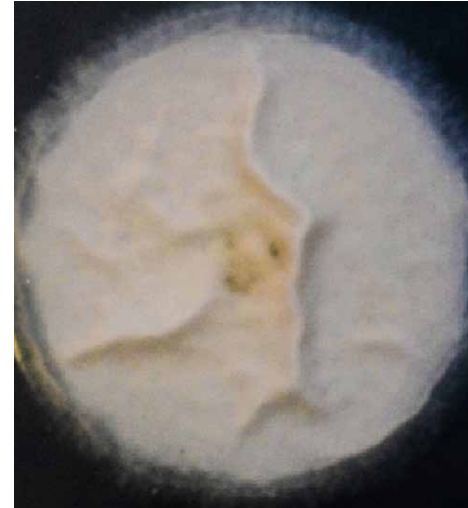Fig. 3.2-12



Day 3, incubation at 37°C. Smoky grey-green and velvety-powdery growth.

*A. fumigatus*, reverse view of culture on SDA

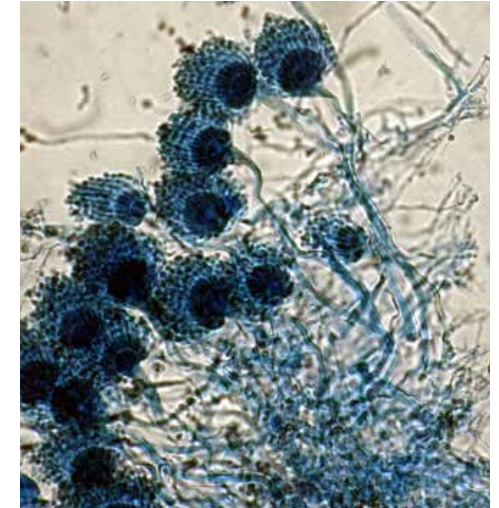Fig. 3.2-13



Day 3, incubation at 37°C. White, pale yellow and tan coloured colonies.

*A. fumigatus*, LPCB wet mount prep

Fig. 3.2-14



Septate hyphae, short conidiophore, flask-shaped vesicles, uniseriate phialides (only on upper two-thirds of vesicle) and columnar conidia. (x40)

*Aspergillus flavus*


Mold found in warm humid soil as well as coloniser of nuts, seeds and legumes where it produces *A. flavus* toxin. It can cause the complete spectrum of aspergillosis. *A. flavus* is unique in its ability to be thermo-tolerant and be able to survive extremes of temperature.

*A. flavus*, front view of culture on SDA Fig. 3.2-15



Day 4, incubation at 37°C. Initial yellow growth which quickly turned bright to dark yellow-green, lime and olive-green.

*A. flavus*, front view of culture on SDA Fig. 3.2-16



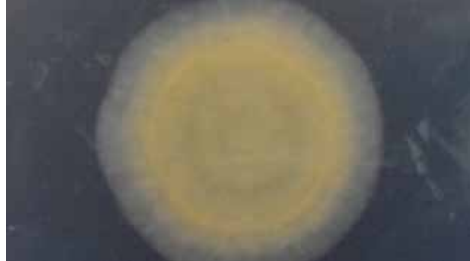Yellow to green coloured colonies.

*A. flavus*, reverse view of culture on PDA Fig. 3.2-17



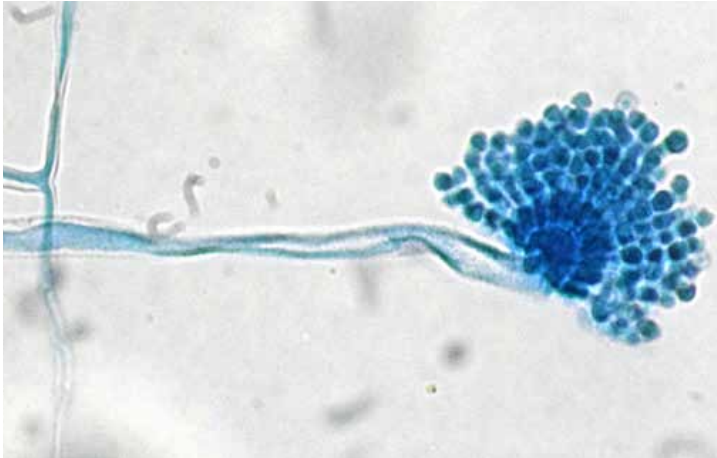Day 4. Tan to white on reverse.

*A. flavus*, reverse view of colony on PDA Fig. 3.2-18



Creamy white to yellow colour.

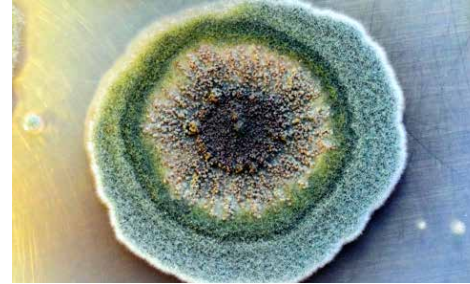*A. flavus*, LPCB wet mount preparation Fig. 3.2-19



Septate hyphae, long conidiophore, uniseriate and (mostly) biseriata phialides, and numerous conidia. (x40)

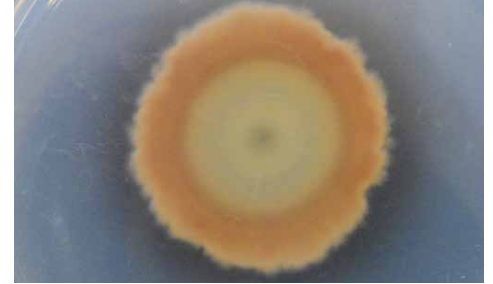*Aspergillus nidulans*

*A. nidulans*, front view of culture on SDA Fig. 3.2-20



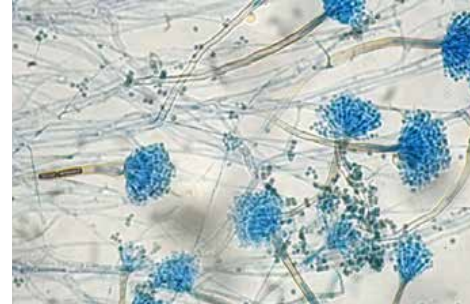
Day 4, incubation at 37°C. Rapid growing velvety green to buff colonies.

*A. nidulans*, reverse view of culture on SDA Fig. 3.2-21



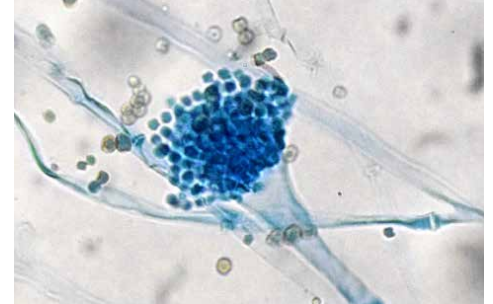Day 4, incubation at 37°C. Buff to brown reverse.

*A. nidulans*, LPCB wet mount preparation Fig. 3.2-22



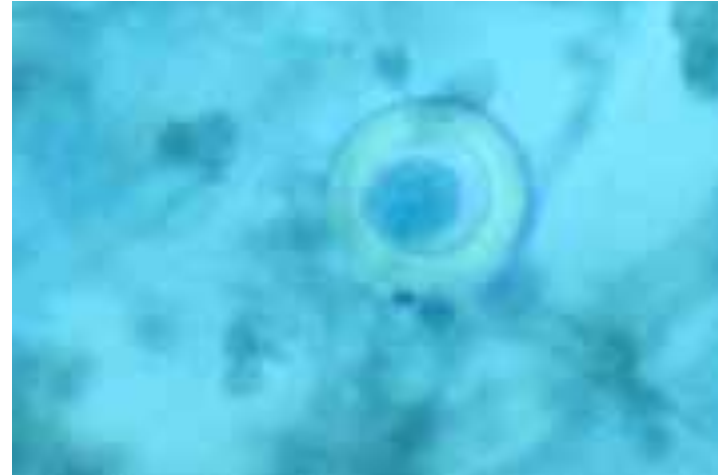Smooth brown pigmented stalk, hemispherical vesicle with metulae and phialides. (x40)

*A. nidulans*, LPCB wet mount preparation Fig. 3.2-23



Close-up of vesicle. (x40)

*A. nidulans*, LPCB wet mount preparation Fig. 3.2-24



Thick-walled globose Hülle cells. (x40)

*Aspergillus terreus*

*A. terreus* is a mold commonly found in soil, compost and dust, and used industrially to produce organic acids and enzymes. Infection mostly manifests as otomycosis and onychomycosis as well as disseminated invasive disease.

*A. terreus*, front view of culture on SDA

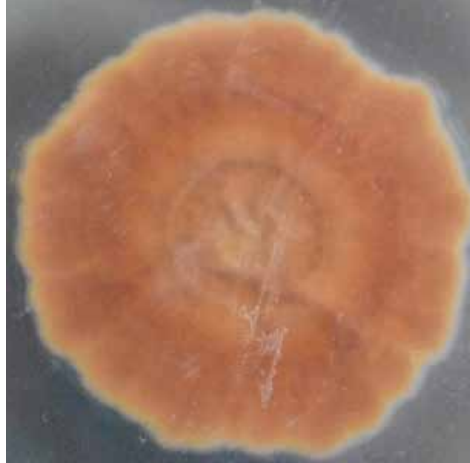Fig. 3.2-25



Day 3, incubation at 37°C. Velvety tan to cinnamon brown growth.

*A. terreus*, reverse view of culture on SDA

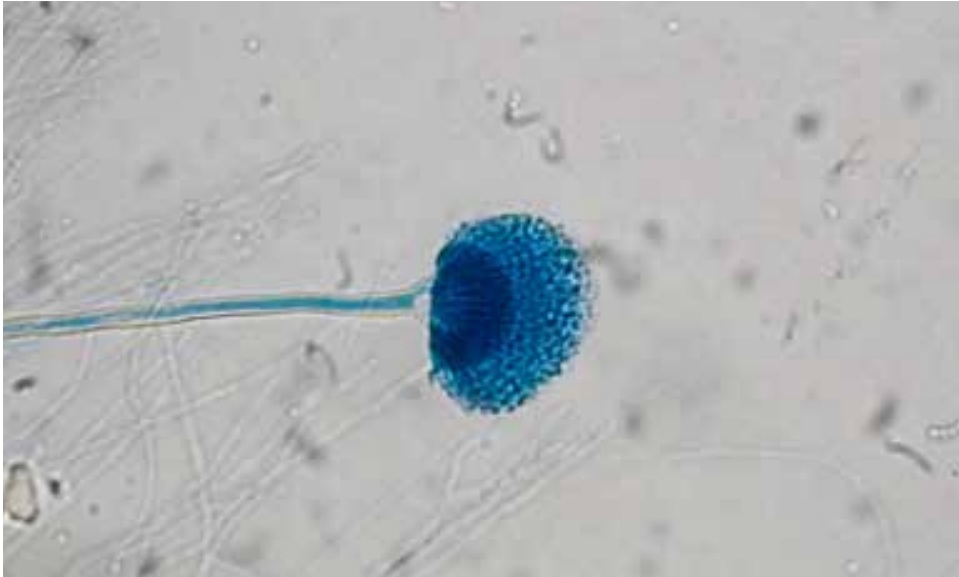Fig. 3.2-26



Day 3, incubation at 37°C. Pale brown reverse.

*A. terreus*, LPCB mount

Fig. 3.2-27



Septate hyphae, relatively short conidiophore, biseriate phialides covering upper half of vesicle, and round and smooth conidia. (x40)

*Aspergillus niger*

*A. niger* is a mold found in soil and indoor environment, affecting fruits and vegetables. It is one of the most common causes of otomycosis which can result in otalgia, hearing loss and at times permanent damage to tympanic membrane.

*A. niger*, front view of culture on SDA

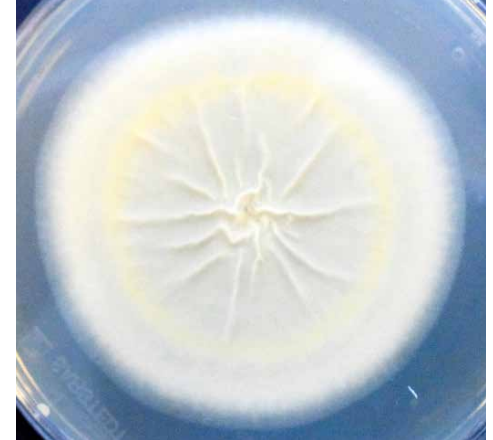Fig. 3.2-28



Day 3, incubation at 37°C. Surface granular in texture with whitish colouration that rapidly turned black at the centre.

*A. niger*, reverse view of culture on SDA

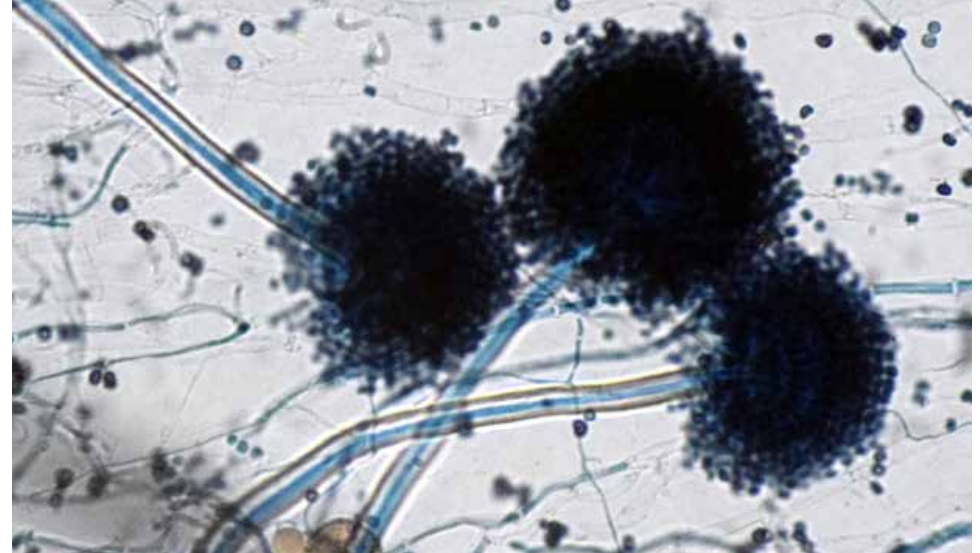Fig. 3.2-29



Day 3, incubation at 37°C. Creamy white to yellow surface.

*A. niger*, LPCB wet mount preparation

Fig. 3.2-30



Three long conidiophores arising from septate hyphae. The central vesicles are completely covered with conidia. (x40)

## Mucoraceous Molds

Kauser Jabeen

### Mucorales

Mucorales includes *Rhizopus*, *Mucor* and *Lichtheimia* molds known for their characteristic black colour and angioinvasive manifestations. Central nervous system mucormycosis is mostly seen as an extension from nose or paranasal sinus with a blackish discharge while acute and rapidly fatal gastrointestinal mucormycosis is seen in patients with extreme malnutrition. Treatment consists of intravenous anti-fungal (lipid formulations of amphotericin B are first-line) and surgical excision of the infected tissue whenever feasible.

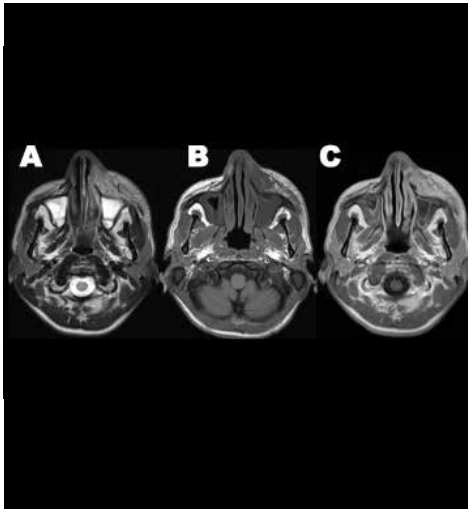
### Clinical Presentation

**Table 3.4: Types of mucormycosis**

<ul style="list-style-type: none"> <li>Central nervous system mucormycosis</li> <li>Rhinocerebral mucormycosis</li> <li>Sinopulmonary mucormycosis</li> <li>Gastrointestinal mucormycosis</li> <li>Disseminated mucormycosis</li> </ul>	<ul style="list-style-type: none"> <li>Rare:                             <ul style="list-style-type: none"> <li>Endocarditis</li> <li>Osteomyelitis</li> <li>Isolated cerebral, renal and peritoneal disease</li> <li>Chronic subcutaneous infection</li> </ul> </li> </ul>
---	---

Rhinocerebral mucormycosis

Fig. 3.3-1

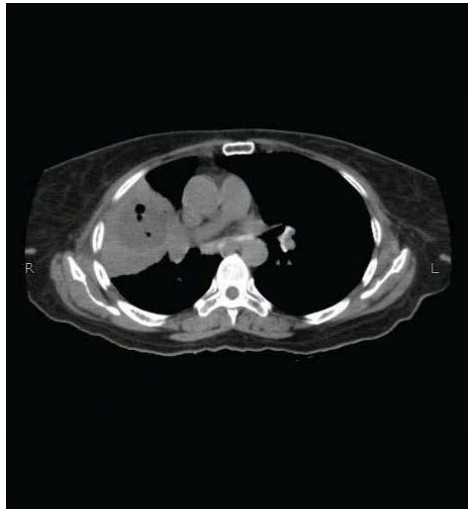

**A.** Axial T2-weighted image shows edema and induration of the left cheek and the left nasolabial fold along with diffuse sinus disease.

**B (pre-contrast) and C (post-contrast).** Axial T1-weighted images show an inflammatory mass with enhancement. Most commonly seen in diabetics. Patients present with facial pain and headache, and development of black ulcers reflects characteristic tissue necrosis.

Pulmonary mucormycosis

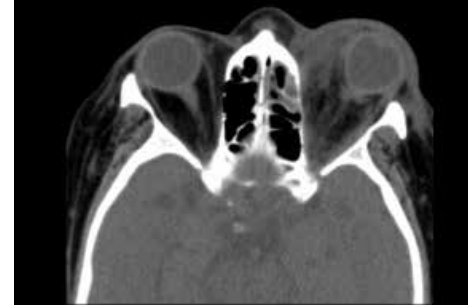Fig. 3.3-2



High resolution CT (HRCT) of chest from a diabetic patient with pulmonary mucormycosis showing consolidation and cavitation in the right middle lobe. Seen mostly in patients with severe immunocompromise. Patients with COPD on chronic steroid treatment are also at risk. Subacute presentation is seen in some patient populations.

Orbital mucormycosis

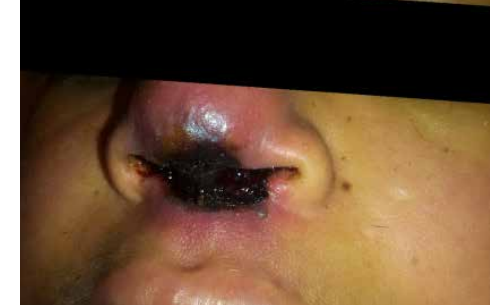Fig. 3.3-3



Non-contrast CT of the orbits shows left-sided proptosis and infiltration of the retrobulbar fat. The orbital globe is deformed consistent with necrosis. The patient had poorly controlled diabetes and presented with loss of vision in the left eye along with periorbital ecchymosis and facial pain. Eventration of the orbit was carried out. Histopathology revealed broad non-septate hyphae consistent with mucormycosis.

Cutaneous mucormycosis

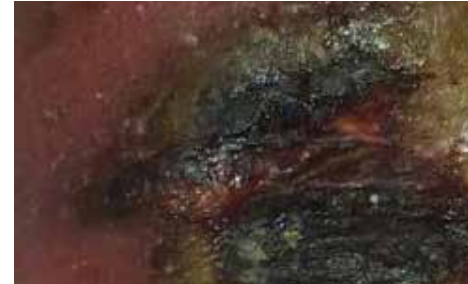Fig. 3.3-4



Typical tissue necrosis. Due to angioinvasive nature of mucoraceous molds, there is ischemia, necrosis and gangrene of tissue. Predominantly involves epidermis and dermis.

Cutaneous mucormycosis

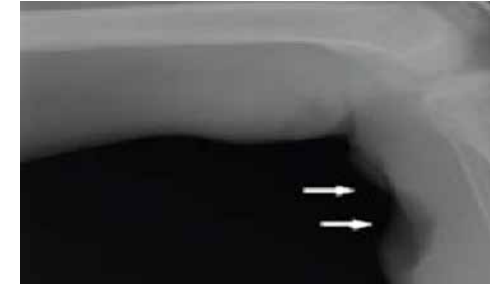
Fig. 3.3-5



Tissue gangrene. Infection is often secondary to trauma, burn, surgery, systemic infection at any other site, and use of contaminated dressings.

Soft tissue mucormycosis

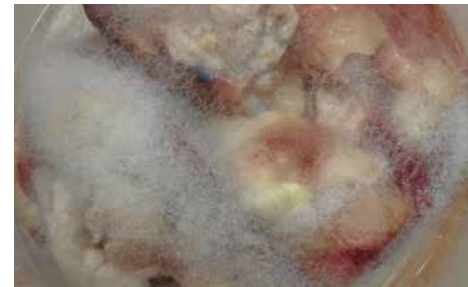Fig. 3.3-6



Plain x-ray shows soft tissue defect in the popliteal and infrapopliteal region of the left lower limb.

Mucorales, growth on tissue on gross examination

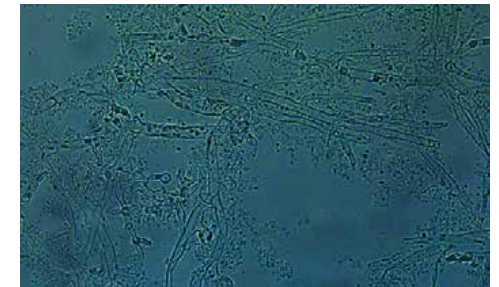
Fig. 3.3-7



Growth of fluffy mucoraceous molds at tissue incubated at room temperature.

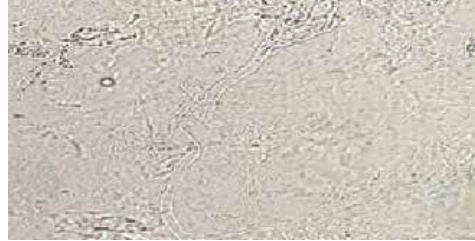
Mucorales, microscopy on 10% KOH wet mount smear

Fig. 3.3-8



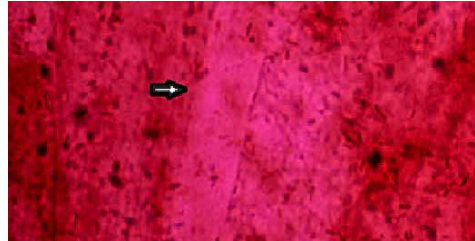
Typical ribbon-like aseptate hyphae. (x40)

Mucorales, microscopy on 10% KOH wet mount smear Fig. 3.3-9



Typical ribbon-like aseptate hyphae. (x40)

Mucorales, H&E stain of tissue Fig. 3.3-11



Broad aseptate hyphae. (x100)

Mucorales, culture on SDA Fig. 3.3-13



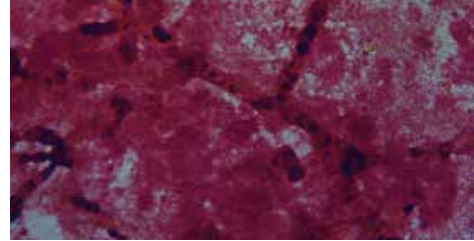
Rapid growth of mucoraceous molds within 12 hours of inoculation.

*Absidia corymbifera*, culture on SDA Fig. 3.3-15



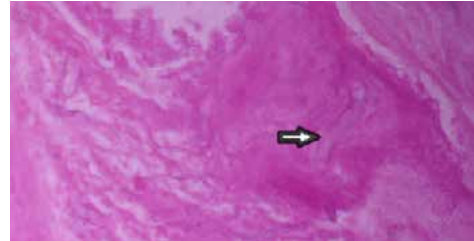
White to pale grey colonies.

Mucorales, Gram stain Fig. 3.3-10



Hyphae of mucoraceous molds. (x100)

Mucorales, H&E stain of muscle tissue Fig. 3.3-12



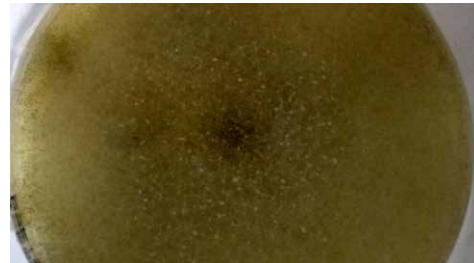Broad aseptate hyphae. (x100)

Mucorales, culture on SDA Fig. 3.3-14



Rapidly growing lid lifter colonies filling the petri dish.

*Mucor* spp., culture on SDA Fig. 3.3-16



White to pale grey colonies.

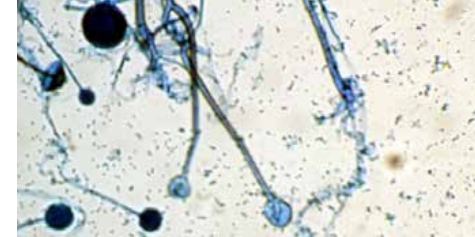
Fig. 3.3-11 Copyright © Wiley Online Library, [Int Wound J 8, 2011, 651-5, doi: 10.1111/j.1742-481X.2011.00839.x]  
 Fig. 3.3-12 Copyright © Wiley Online Library, [Int Wound J 8, 2011, 651-5, doi: 10.1111/j.1742-481X.2011.00839.x]

*Rhizopus* spp., culture on SDA Fig. 3.3-17



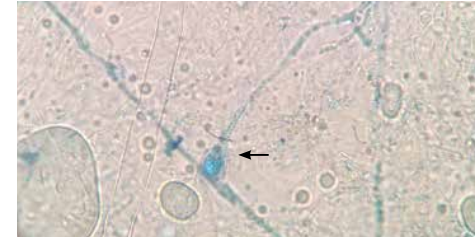
Grey-to-black older colonies around the rim of the plate.

*Rhizopus* spp., LPCB wet mount preparation Fig. 3.3-19



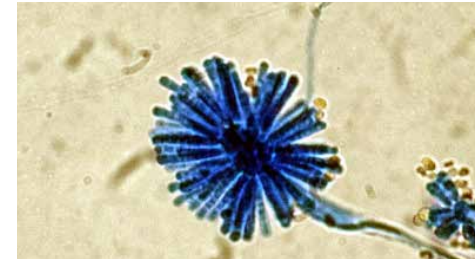Round sporangia and nodal rhizoids. (x10)

*Apophysomyces* spp., LPCB wet mount preparation Fig. 3.3-21



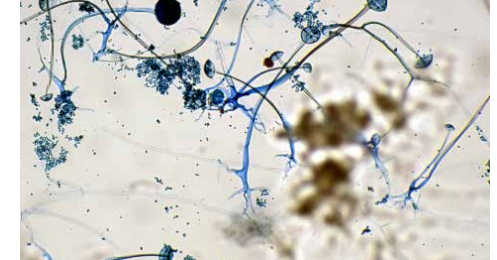
Pear-shaped sporangia and prominent apophysis (arrow). This mold is very difficult to sporulate. (x40)

*Syncephalastrum* spp., LPCB wet mount preparation Fig. 3.3-23



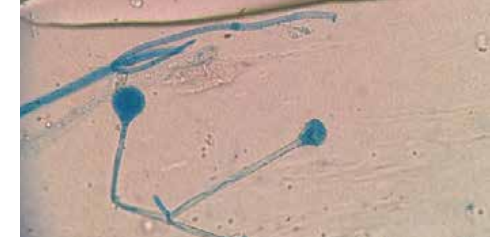Finger-like tubular sporangia arranged on a vesicle. (x40)

*Rhizomucor* spp., LPCB wet mount preparation Fig. 3.3-18



Round sporangia and internodal rhizoids. (x40)

*Absidia* spp., LPCB wet mount preparation Fig. 3.3-20



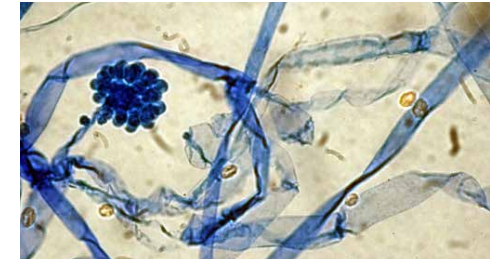
Small pear-shaped sporangia. (x10)

*Saksenaia vasiformis*, LPCB wet mount preparation Fig. 3.3-22



Flask-shaped sporangia. This mold is very difficult to sporulate. (x40)

*Cunninghamella* spp., LPCB wet mount preparation Fig. 3.3-24



Vesicles covered with spine-like denticles. (x40)

### Entomophthorales

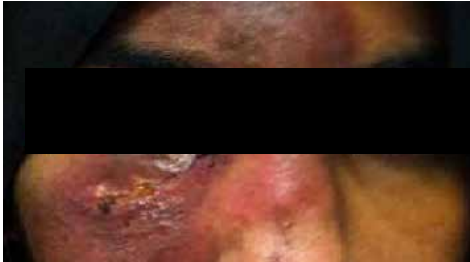In immunocompetent hosts, *Entomophthorales* cause distinct cutaneous syndromes (entomophthoromycosis). In immunocompromised hosts, the species causes rare opportunistic pulmonary and disseminated infection similar to that of Mucorales fungi. Some species have a predilection for certain sites:

- *Basidiobolus ranarum* is a cause of subcutaneous infection, also known as basidiobolomycosis.
- *Conidiobolus coronatus* or *Conidiobolus incongruus* is the most common cause of rhinofacial infection, also known as conidiobolomycosis.

### Clinical Presentation

Subcutaneous entomophthoromycosis

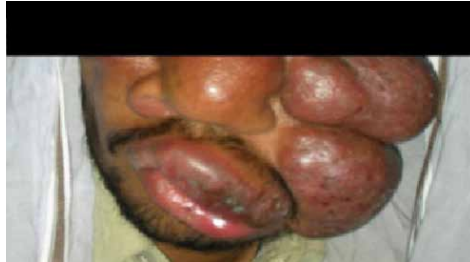Fig. 3.3-25



Extensive tissue ischemia and necrosis secondary to infection with *Basidiobolus* spp.

Chronic subcutaneous infection

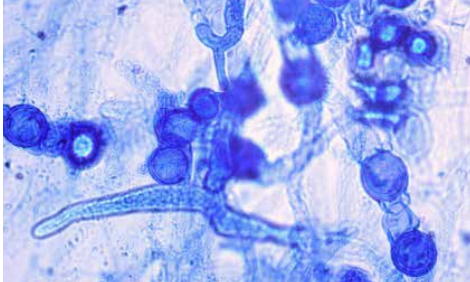
Fig. 3.3-26



Visible deformation of facial contours secondary to infection with *Conidiobolus* spp.

*Basidiobolus* spp., LPCB wet mount preparation

Fig. 3.3-27



Club shaped spores and intercalary zygospores. (x100)

*Conidiobolus* spp., culture plate

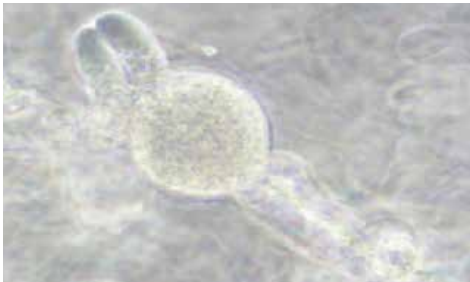Fig. 3.3-28



White colonies.

*Basidiobolus* spp., wet mount preparation

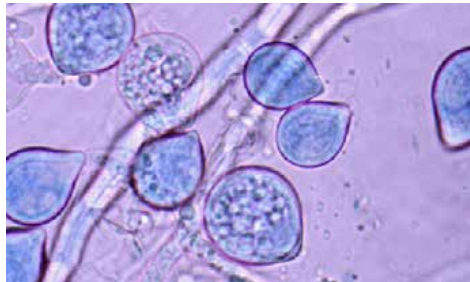Fig. 3.3-29



Direct microscopy from tissue biopsy reveals parrot beak shaped zygospore. (x40)

*Conidiobolus* spp., LPCB wet mount preparation

Fig. 3.3-30



Single-celled round spores that later bear a broad tapering projection. (x40)

### Dermatophytes

Afia Zafar

Dermatophytes are a group of closely related fungi that can be described as anthropophilic, zoophilic or geophilic depending upon whether their normal habitat is human being, animal or soil. Dermatophytoses or infection of superficial keratinised tissues (skin, nail and hair) are characterised by ring-shaped lesion. Skin scrapings show hyaline septate branching hyphae or arthroconidia.

Table 3.5: Dermatophytes

Epidermophyton	Trichophyton	Microsporum
<i>E. floccuosum</i>	<i>T. mentagrophytes</i> <i>T. rubrum</i> <i>T. verrucosum</i> <i>T. tonsurans</i> <i>T. violaceum</i>	<i>M. canis</i> <i>M. audouinii</i> <i>M. equinum</i> <i>M. fulvum</i> <i>M. gypseum</i>

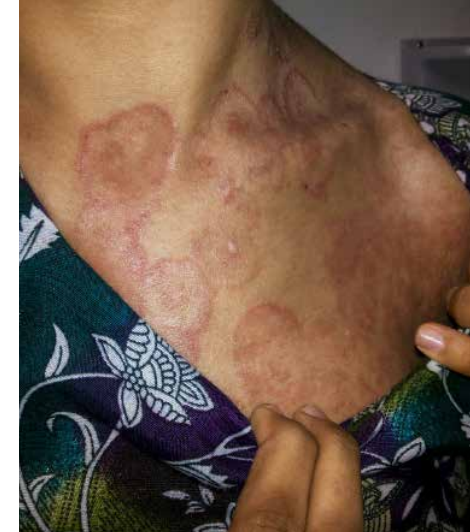Table 3.6: Types of dermatophytoses

- Tinea capitis (head)
- Tinea corporis (body)
- Tinea pedis (foot)
- Tinea barbae (face)
- Tinea unguinum (nail)

### Clinical Presentation

Tinea corporis

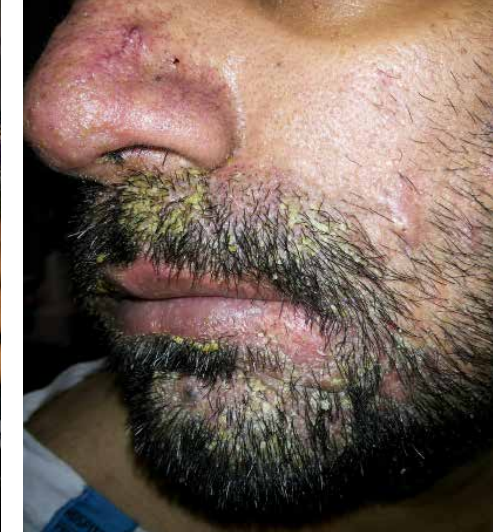Fig. 3.4-1



Female patient presented with a 3-week history of itchy rash on chest and recent development of erythematous annular plaques of variable sizes. Lesions resolved after treatment with systemic and topical antifungals.

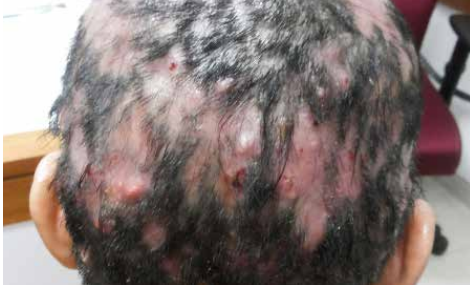Tinea barbae with secondary bacterial infection

Fig. 3.4-2



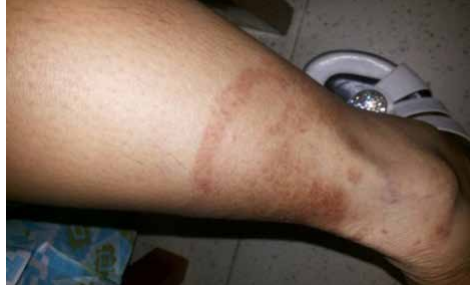Male patient presented with 2-month history of itchy erythematous rash with inflammatory papules and pustules localised to coarse facial hair (beard). Lesions resolved after improvement in hygiene and treatment with systemic and topical antifungals, and antibiotics.

**Tinea capitis** Fig. 3.4-3



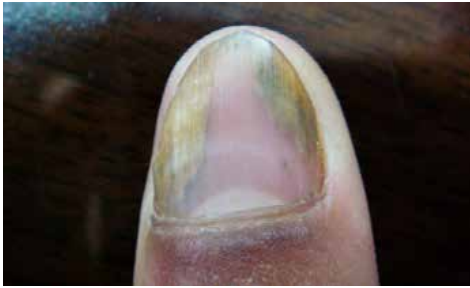Patient presented with 6-week history of patchy hair loss, erythema, nodular and pustular lesions, kerion formation, and scarring. Lesions resolved after treatment with systemic terbinafine for 8 weeks and topical antifungal.

**Tinea corporis** Fig. 3.4-4



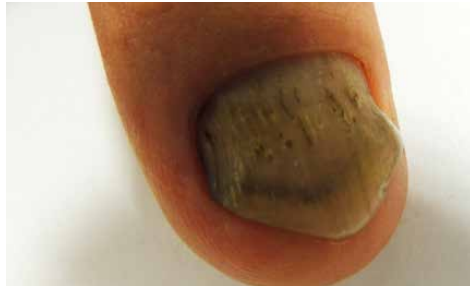Female patient presented with 1-month history of an itchy and enlarging annular plaque lesion on leg. Treated with topical antifungals.

**Onychomycosis** Fig. 3.4-5



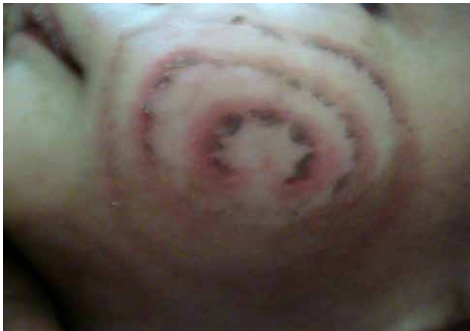Patient presented with 3-month history of progressive thickening and discolouration of nail plate with paronychia. Responded to 2-month long pulse therapy with itraconazole.

**Tinea unguium** Fig. 3.4-6



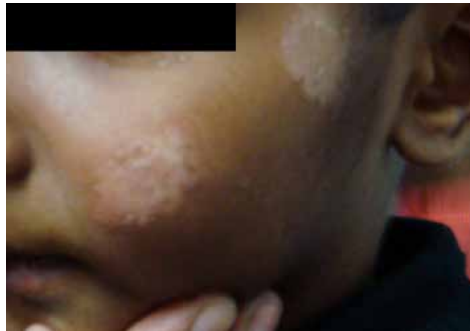Ridging, onycholysis, thickening and discolouration of nail plate. Visible inflammation of nails folds.

**Tinea imbricata (Tokelau) caused by Tinea concentricum** Fig. 3.4-7



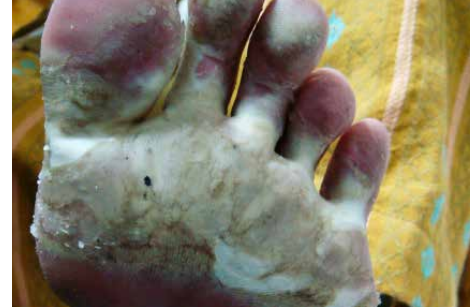Young patient presented with 3-week history of pruritic and crusting annular concentric rings on face. Responded to treatment with topical antifungals and improved hygiene.

**Tinea faciei** Fig. 3.4-8



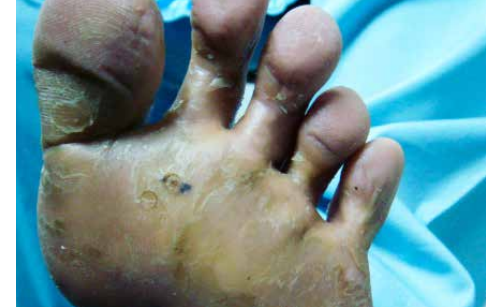Young patient presented with 3-week history of erythematous and scaly plaques on face. Treated with topical antifungals.

**Tinea pedis (before treatment)** Fig. 3.4-9



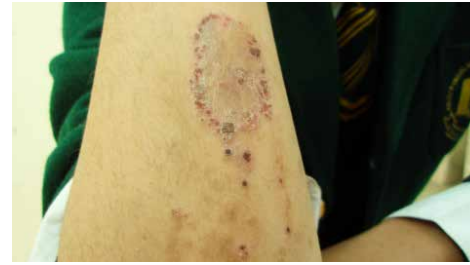Patient presented with a 5-week history of intertriginous dermatitis of toes that spread to involve the sole of the foot. Characterised by peeling, maceration and fissuring of skin.

**Tinea pedis (after treatment)** Fig. 3.4-10



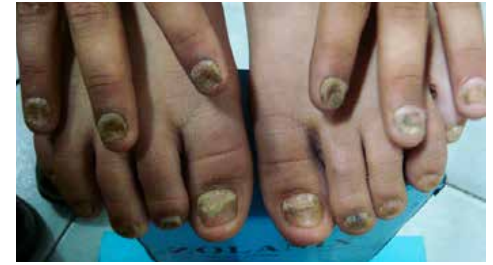Patient responded to 6-week therapy of oral terbinafine and topical antifungals, and improved hygiene.

**Tinea corporis** Fig. 3.4-11



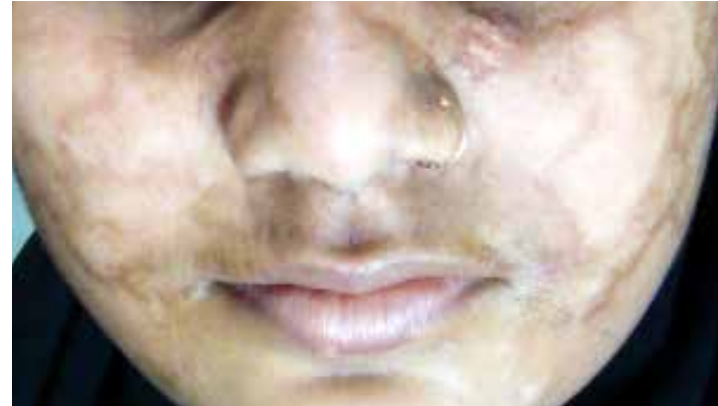Patient presented with 2-week history of multiple, itchy annular plaques on arm. Responded to topical antifungals.

**Onychomycosis** Fig. 3.4-12



Patient presented with 12-month history of nail dystrophy of one toe nail gradually involving all toe and finger nails on both hands and feet. There was progressive discolouration, thickening and crumbling of nail plates with some degree of onycholysis. Treated with oral terbinafine.

**Pityriasis versicolor** Fig. 3.4-13



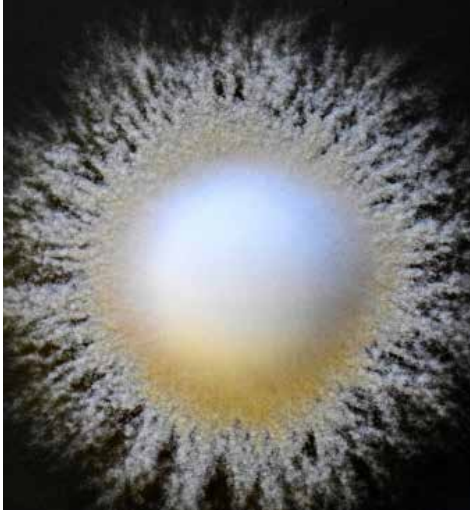Female patient presented with 5-month history of discrete and confluent asymptomatic patches of hypo- and hyperpigmentation with mild scaling on face. The lesions gradually extended to involve the trunk. Treated with topical antifungals and systemic fluconazole (weekly for 1 month), and counselled about improving hygiene. The causative agent is *Malassezia furfur*.

**Microsporum canis**

*M. canis* is typically hosted by cats and dogs (zoophilic), and causes infections in humans through transmission by direct and indirect contact. It is the most common cause of tinea capitis and tinea corporis in humans. On microscopic examination, it displays characteristic macroconidia as well as microconidia.

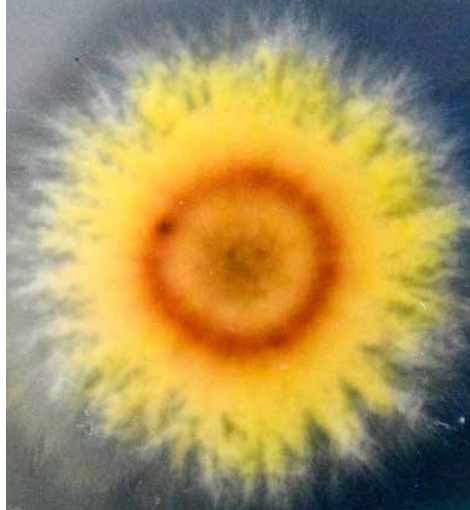*M. canis*, front view of culture on SDA

Fig. 3.4-14



*M. canis*, reverse view of culture on SDA

Fig. 3.4-15

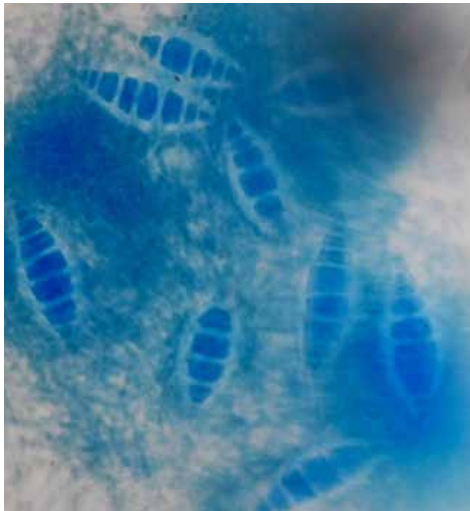

Slow growing (5 cm in 1 week), pale buff to white colony, with yellow to colourless radiating edge.

Bright yellow to colourless at the edge.

*M. canis*, LPCB wet mount preparation

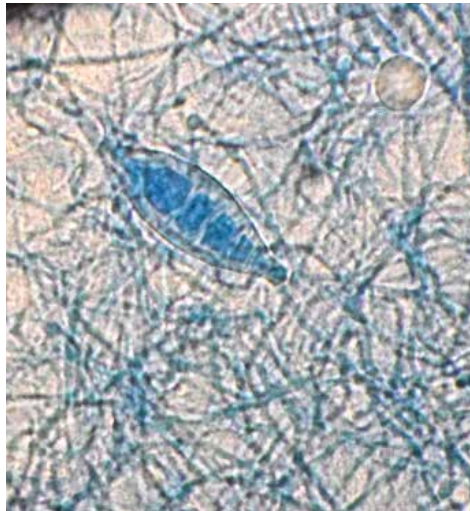
Fig. 3.4-16



Predominantly large macroconidia concentrated in the centre of the colony. (x10)

*M. canis*, LPCB wet mount preparation

Fig. 3.4-17



Spindle-shaped microconidium with rough thickened wall and curved to one side. (x40)

**Microsporum gypseum**

*M. gypseum* is commonly found in humid soil (geophilic), and results in hair, skin and nail infections.

*M. gypseum*, front view of culture on SDA

Fig. 3.4-18



Slow growing colony (4-5 cm in 1 week), powdery in texture and buff to cinnamon colour.

*M. gypseum*, front view of culture

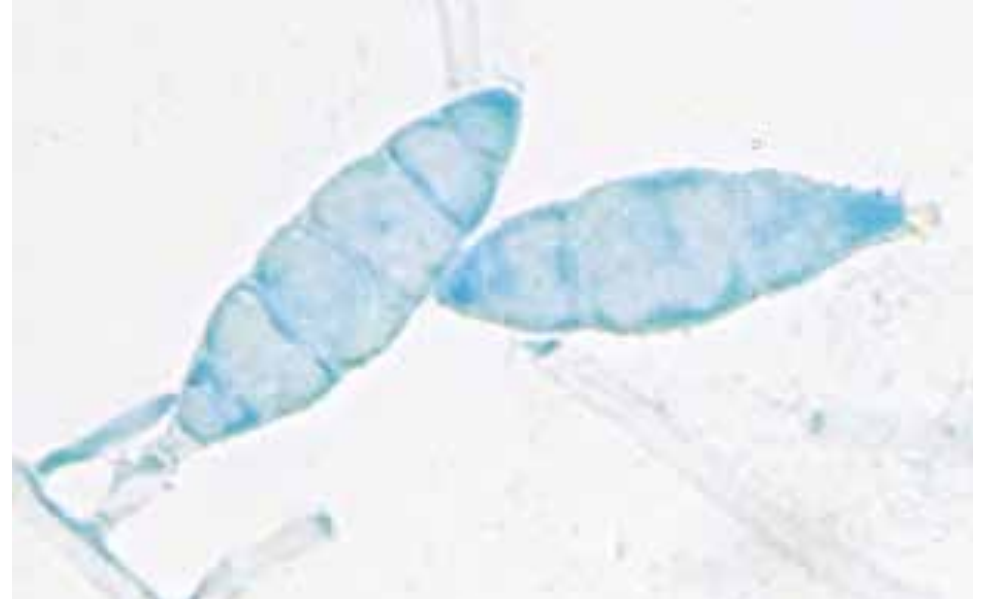Fig. 3.4-19



Buff to pinkish colour colony.

*M. gypseum*, LPCB wet mount preparation

Fig. 3.4-20



Numerous macroconidia and very few microconidia. Macroconidia are elliptical with thin roughened walls and 4-6 septa. (x40)

*Trichophyton rubrum*

*T. rubrum* is an obligate human pathogen not found in environment. It is a common cause of athlete's foot, ring worm and jock's itch.

*T. rubrum*, reverse view of culture plate

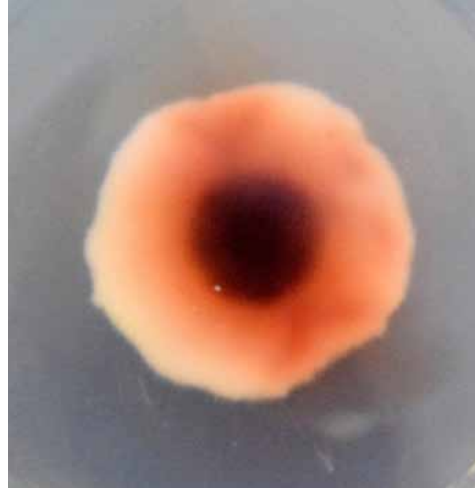


Fig. 3.4-21

*T. rubrum*, LPCB wet mount preparation

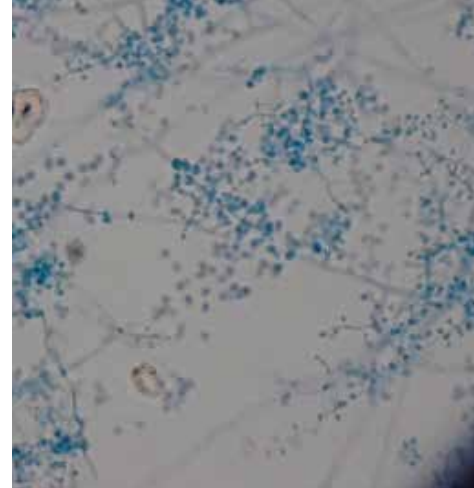


Fig. 3.4-22

Deep red, brown, yellow and orange coloured colony. White granular or fluffy colonies on front.

Sparse clubbed microconidia, formed along the sides of the hyphae. Macroconidia absent. (x10)

*T. rubrum*, LPCB wet mount preparation



Fig. 3.4-23

Aleurosporulation. (x40)

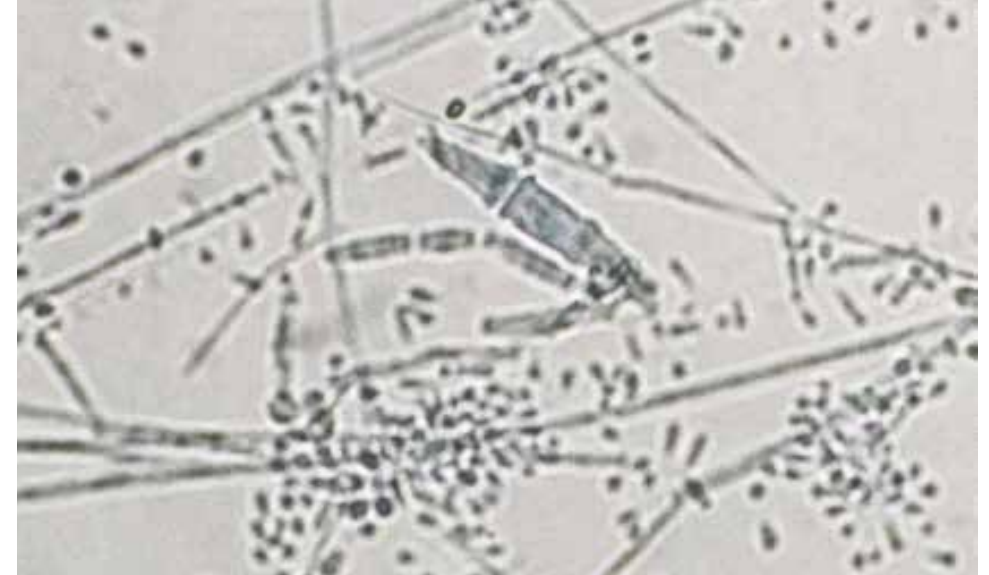
*Trichophyton mentagrophytes*

*T. mentagrophytes* is found in warm and humid places such as swimming pools and public showers, and results in tinea capitis, tinea corporis, and tinea pedis.

Culture on SDA shows flat powdery to granular colonies that appear white to cream on front and cream to brown on reverse with radiations (not shown).

*T. mentagrophytes*, LPCB wet mount preparation

Fig. 3.4-24



Numerous round, smooth-walled microconidia along branching hyphae. Typically found in dense clusters. Macroconidia are cylindrical with thin walls and 3-4 septa. Sometimes spiral hyphae are seen (not shown). (x40)

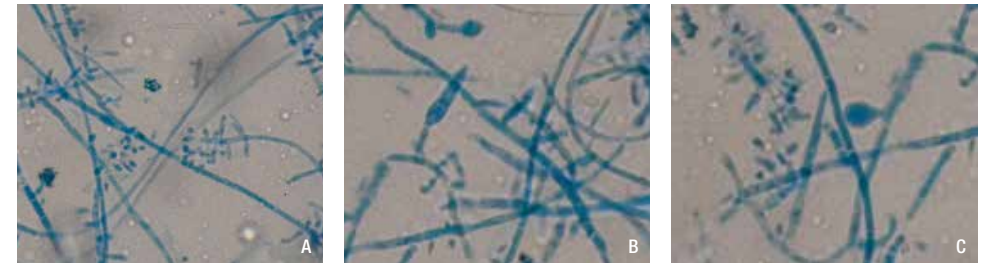
*Trichophyton tonsurans*

*T. tonsurans* is found in indoor environments, and causes tinea capitis and tinea corporis.

Colonies on SDA are white powdery, flat sometime folded in the centre in the front and yellow to reddish brown on reverse (not shown).

*T. tonsurans*, LPCB wet mount preparation

Fig. 3.4-25



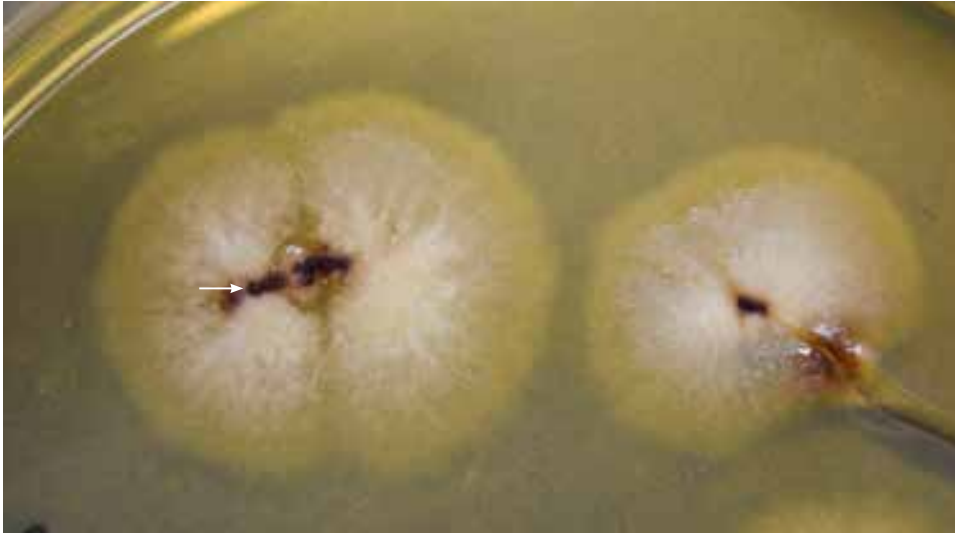(A) Abundant microconidia, large oval to club shaped, growing alongside hyphae; (B) Numerous macroconidia; (C) Up to 10 septa sometime loose content and structure. (x40)

### Trichophyton violaceum

*T. violaceum* is commonly found in environment, and usually isolated in tinea capitis. Microscopically, *T. violaceum* reveals septate hyphae, often distorted, with micro- and macroconidia extremely rare (not shown).

Mixed culture of *T. violaceum* and *T. tonsurans*, front view of culture plate on SDA

Fig. 3.4-26



Glabrous textured, heaped-up purple-to-deep red colonies of *T. violaceum* (marked by arrow) growing on SDA from skin scrapings of a taenia imbricata patient. Larger buff-coloured felt-like colonies of *T. tonsurans* can also be observed arising from the same site. Both isolates have the same colour on front and reverse. Growth of *T. violaceum* is very slow, taking more than 7 days; *T. tonsurans* is relatively faster, taking 4-5 days.

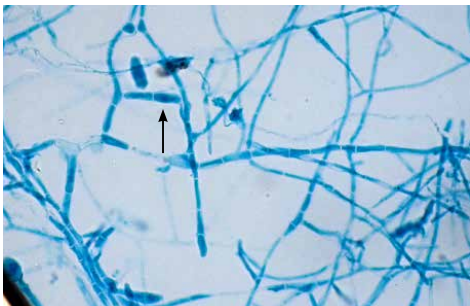
### Epidermophyton flocculosum

*E. flocculosum* is a common flora of humans, domesticated and wild animals, and found in gyms and showers. It is known to cause tinea pedis, tinea cruris, tinea corporis and onychomycosis.

Culture on SDA shows flat, powdery khaki colonies with colourless submerged edges in front and pale brown on reverse (not shown).

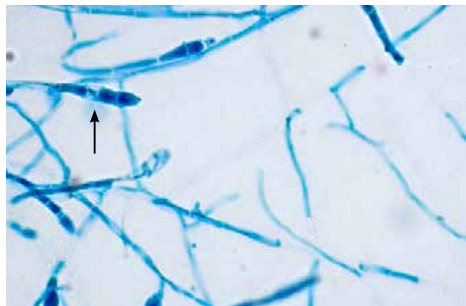
*E. flocculosum*, LPCB wet mount preparation

Fig. 3.4-27



Long septate macroconidia arising in a cluster

Fig. 3.4-28



Predominantly oval- and club-shaped macroconidia with smooth medium thickness walls and 2-4 septa. (x40)

### Hyaline Molds

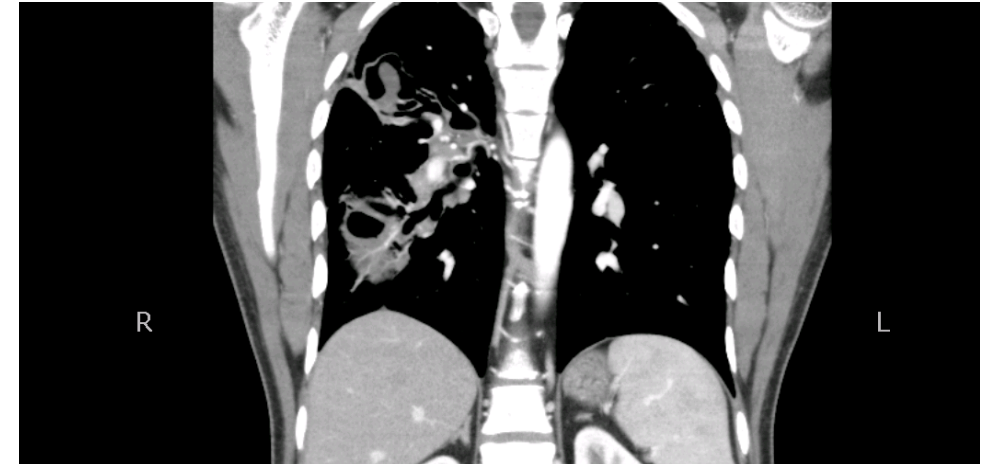
Kausar Jabeen and Joveria Farooqi

The fungi causing hyalohyphomycosis are characterised by the presence of septate, hyaline and non-pigmented hyphae. Notable fungi in this group include *Fusarium*, *Penicillium*, *Scedosporium*, *Acremonium*, *Paecilomyces*, *Trichoderma* and *Scopulariopsis*. Depending on the immune status of the host, infection caused by these fungi varies from colonisation, superficial infections and subcutaneous infections to disseminated diseases. Most fungi in this group cause life-threatening opportunistic infections. Many of the hyaline molds exhibit decreased susceptibilities to several antifungal agents.

### Clinical Presentation

Pneumonia secondary to *Pseudallescheriasis*

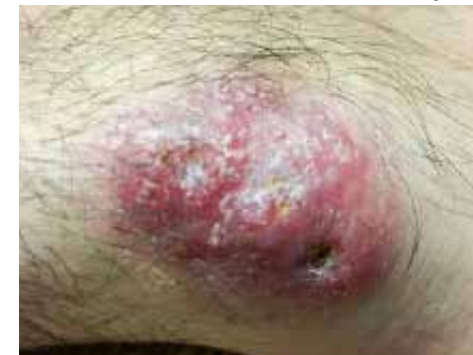Fig. 3.5-1



Computed tomography scan of chest shows two thick-walled cavities in right lung resulting from *Scedosporium apiospermum*. The first cavity measuring 4.2 by 2.4 cm has a small fungal ball. The second larger cavity (10 by 4.5 cm) in the right lower lobe has a fungal ball measuring 47 by 29 mm, which extends across major fissure to involve the upper lobe as well.

Chronic skin infection

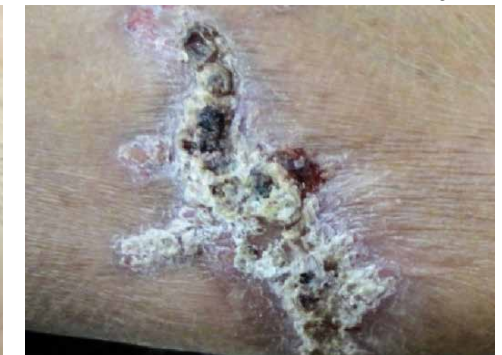Fig. 3.5-2



Nodular lesion caused by *Fusarium* species.

Chronic skin infection

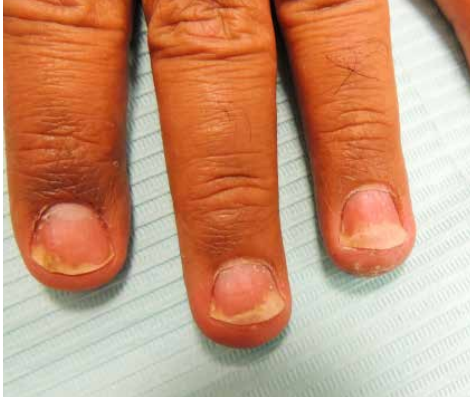Fig. 3.5-3



An ulcerative lesion caused by *S. apiospermum*.

Fig. 3.5-1 Copyright © Springer, [Infection, 44, 2016, 127-32, doi: 10.1007/s15010-015-0840-4]

**Onychomycosis**

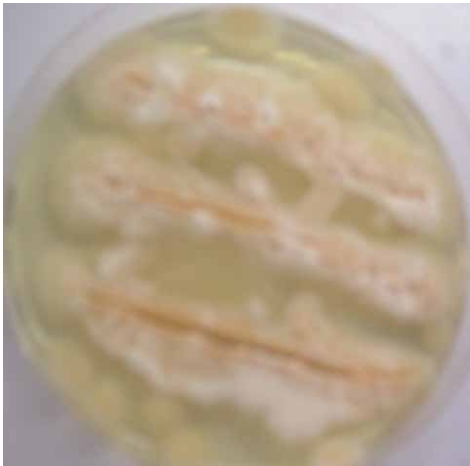

Nail infection caused by *Acremonium* species.

***Acremonium* species**

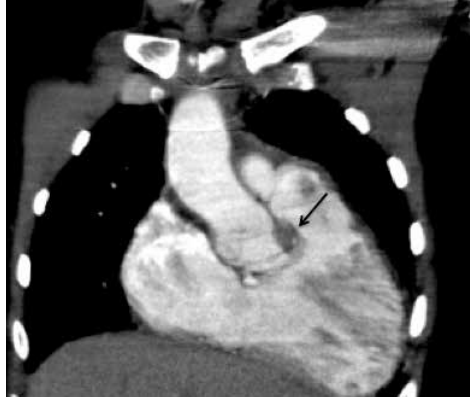
*Acremonium* is an environmental pathogen typically found in soil, and infection is secondary to penetrating trauma. Common agent of nail infections, mycetoma and corneal infections, and can cause disseminated infections in immunosuppressed patients.

*Acremonium* spp., front view of culture on SDA Fig. 3.5-6



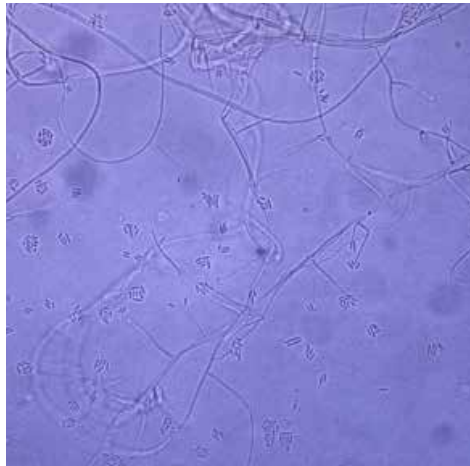
Colonies grow rapidly and mature in 5-7 days. Texture of colonies could be powdery, cottony or felt like. Colour of colonies will vary according to species to white, light pink, pale rose, yellowish with a colourless reverse.

Fig. 3.5-4 Cardiac vegetation



Coronal contrast-enhanced CT scan reveals cardiomegaly, a right-sided aortic arch and dehiscence of the ventricular septal defect repair. There is focal thickening at the aortic valve and margin of the reformed VSD (arrow). *Acremonium* was cultured on surgically excised valve tissue.

*Acremonium* spp., microscopic examination Fig. 3.5-7

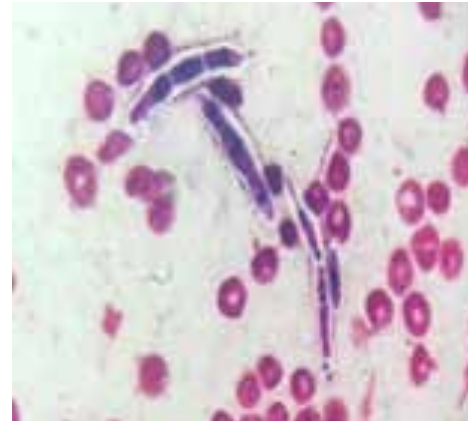


Septate hyphae arranged in distinct bundles. Conidiophores are long, erect and delicate; they bear clusters of conidia arranged as wet masses on the tip. These conidia are easily disrupted from the tip of conidiophore. (x10)

***Fusarium* species**

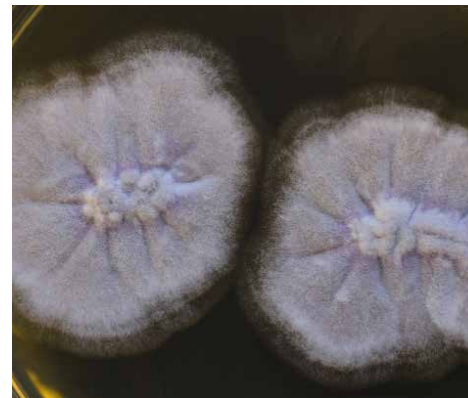*Fusarium* is commonly found in soil and debris, and inoculation occurs following trauma, instrumentation or insertion of contaminated central venous lines. In immunocompetent patients, *Fusarium* may cause superficial nail and soft tissue infections as well as peritoneal and osteoarticular infections. Populations that are most at risk for invasive disease are patients with hematological malignancies and bone marrow transplant patients. Cutaneous lesions are present in 60 to 80 per cent of disseminated fusariosis, and blood cultures are frequently positive. The characteristic feature of *Fusarium* species on culture is the production of sickle-shaped multiseptate macroconidia.

*Fusarium* spp., Gram stain from positive blood culture sample



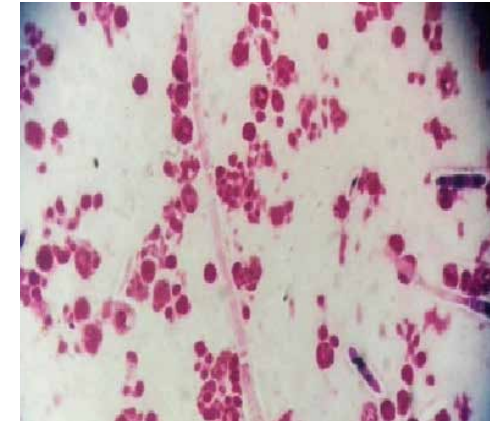
Septate hyphae and typical canoe-shaped macroconidia. The mold was later identified as *Fusarium* species. (x100)

*Fusarium* spp., front view on SDA Fig. 3.5-9

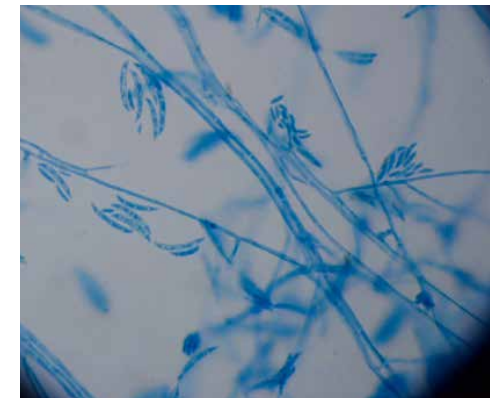


Colonies grow rapidly and mature in 3-5 days. Colonies are initially white but later may develop pink, orange, purple or peach tinge depending on species. Reverse is pale but may be dark depending on species.

Fig. 3.5-8



*Fusarium* spp., LPCB wet mount preparation Fig. 3.5-10



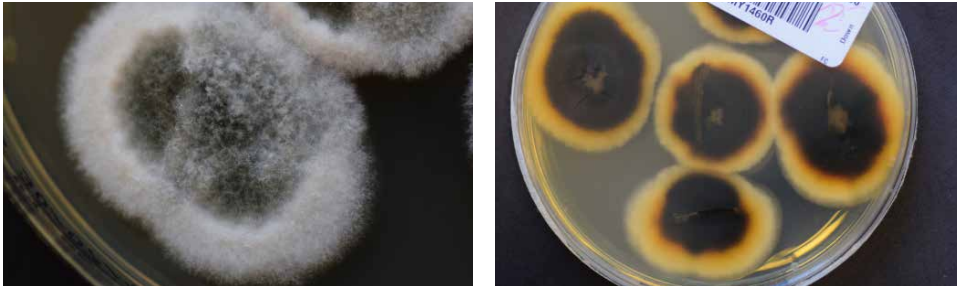
Septate hyphae with short tapering conidiophore (conidiophore may be long in some species) are seen. These conidiophore bear sickle-shaped, banana-shaped or canoe-shaped macroconidia with three to five septa. Sparse to abundant microconidia arranged singly or in slimy balls could also be seen depending on species. (x40)

### Scedosporium species

*Scedosporium* is mainly found in the environment and can be responsible for a spectrum of infections ranging from mycetoma to disseminated infections depending on host immunity status. The species is notorious due to its neurotropic tendency and antimicrobial resistance. Clinically significant species are *S. apiospermum*, *S. boydii* and *S. prolificans*. *S. prolificans* especially is resistant to virtually all antifungal classes and is associated with high mortality.

#### *Scedosporium apiospermum*

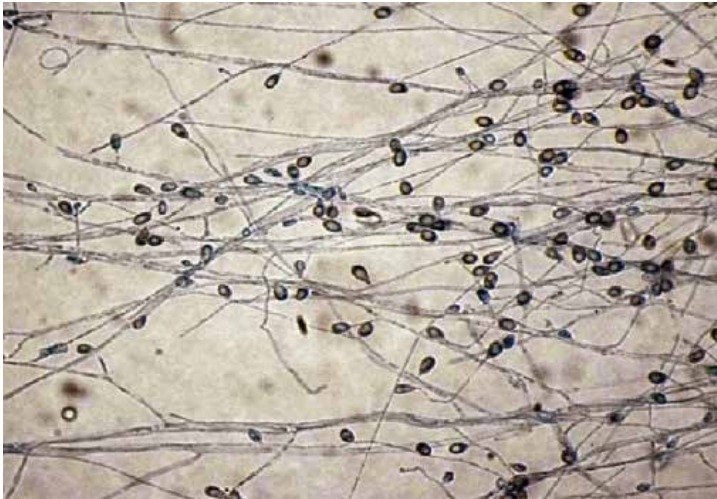
*S. apiospermum*, front view of culture on SDA Fig. 3.5-11 *S. apiospermum*, reverse view of culture on SDA Fig. 3.5-12



Colonies grow rapidly and mature in 5 to 7 days. Front view initially shows colonies that are white but later turn grey.

Initially white and then turns dark brown or black.

*S. apiospermum*, LPCB wet mount preparation Fig. 3.5-13



Septate hyphae with short and long conidiophores. These conidiophore bear oval conidia arranged singly or in small clusters. Occasionally conidiophores are arranged in bundles (Graphium state) that diverge and at the edge bear single conidia. The sexual stage can be induced by subculturing on CMT or PDA. Ascocarps are black and round with elliptical ascospores. (x40)

#### *Scedosporium prolificans*

Colonies grow rapidly and mature in 5 days. Colonies are grey to brownish, spreading, with scant, cobweb appearance (not shown). On reverse view, colonies appear dark grey to black. On microscopy, septate hyphae bearing short conidiophores are seen. Conidiophores have swollen base and long tapering tip that bear conidia singly or in clumps at the apex. Conidia are pigmented, oval or round with a truncated base.

### Paecilomyces species

*Paecilomyces* have been rarely implicated as a cause of invasive infection in immunosuppressed patient and skin infection in immunocompetent patients. Morphologically they resemble *Penicillium* species, however, their colonies are never green or blue-green and they have long, slender and divergent phialides.

#### *Paecilomyces variotii*

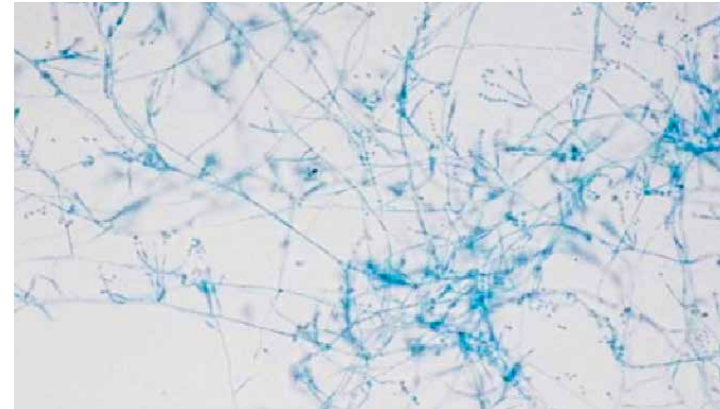
Colonies grow rapidly and mature in 3-5 days, are olive brown in colour with a pale reverse (not shown).

On microscopy, phialides are elongated, swollen at bases and taper into a long neck. These phialides may occur singly, in pairs, in leaf-like pattern or in brush-like pattern (not shown).

#### *Purpureocillium lilacinum*

Colonies are white changing to lilac with a pale or deep purple reverse.

*P. lilacinum*, LPCB wet mount preparation Fig. 3.5-14

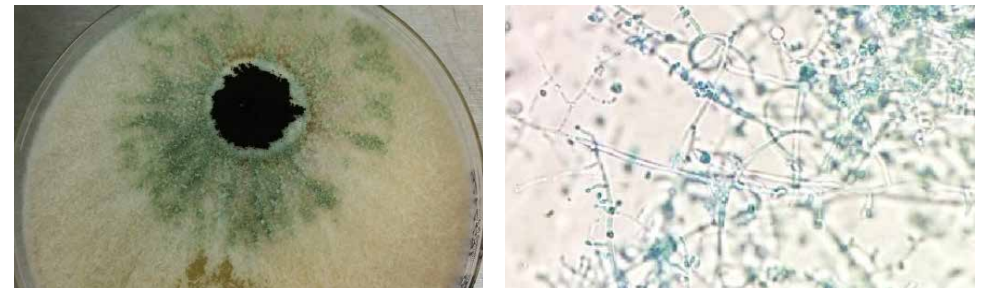


Phialides are densely clustered. These phialides bear long divergent chains of hyaline to pigmented, smooth or rough, sub-spherical to oval single-celled conidia. Previously called *Paecilomyces lilacinum*. (x10)

### Trichoderma species

*Trichoderma* is commonly found in soil as well as air. Its typical clinical manifestations include localised cutaneous lesions, peritonitis complicating peritoneal dialysis, pulmonary disease (fungus ball), and disseminated infections. Antimicrobial activity is variable and surgical resection of localised infection is recommended whenever feasible.

*Trichoderma* spp., front view of culture on SDA Fig. 3.5-15 *Trichoderma* spp., LPCB wet mount preparation Fig. 3.5-16



Colonies grow rapidly, fill the petri dish and mature in 5 days. Colour of colonies is initially white and later develops green patches with a colourless or tan reverse.

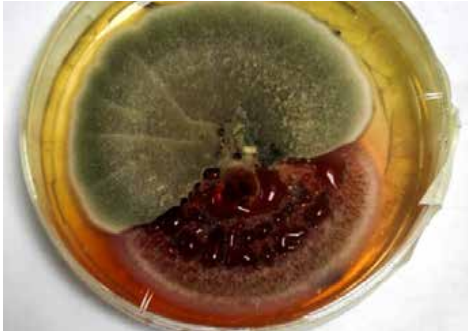On microscopy hyphae are septate and bear short and often branched conidiophores. Conidiophores have phialides with broad bases and narrow apex that in turn have clusters of round, single celled conidia. (x10)

### Penicillium species

*Penicillium* is commonly found in soil, damp objects and spaces, and can contaminate food (most common cause of spoilage of fruits and vegetables). Characterised by their blue and green colour due to the large quantities of green, blue and yellow spores produced.

*P. marneffeii*, front view of culture on SDA

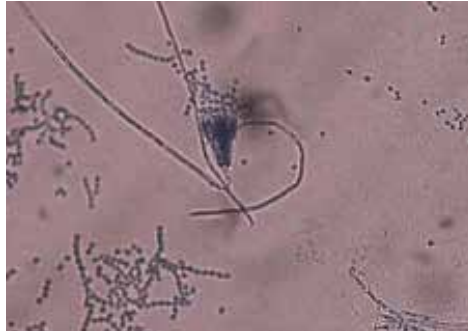Fig. 3.5-17



Colonies are bluish grey-green, later turning yellowish red with diffusible red pigment. This species is the only dimorphic *Penicillium* species, converting to white to tan, dry, soft yeast-like colonies at 37°C in 7-14 days on SBA or Brain Heart Infusion agar.

*P. marneffeii*, LPCB wet mount preparation

Fig. 3.5-18



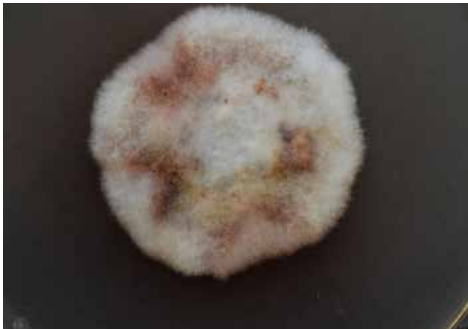Microscopic morphology of *Penicillium* species resembles a broom: phialides consist of 3-5 metulae, depending on species, and chains of spherical to oval conidia arising in basipetal pattern. The absence of a vesicle differentiates it from *Aspergillus* spp., while multiple phialides arising from a single conidiophore distinguish it from *Scopulariopsis* spp.

### Chrysosporium species

Commonly found in soil and debris as well as indoors in damp wood, cellulose structures and wallpaper. *Chrysosporium* spp. can result in severe invasive disease in immunosuppressed patients. Unlike *Penicillium*, it produces pyriform conidia with truncated bases.

*Chrysosporium* spp., front view on SDA

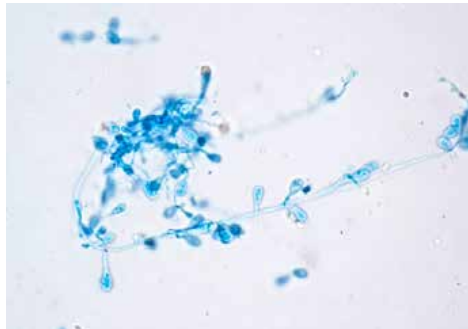Fig. 3.5-19



Colonies grow rapidly and mature in 5-7 days. Depending on species colour of colonies varies from white to tan to pink or light orange with a white or tan reverse (highly variable depending on species).

*Chrysosporium* spp., LPCB wet mount preparation

Fig. 3.5-20



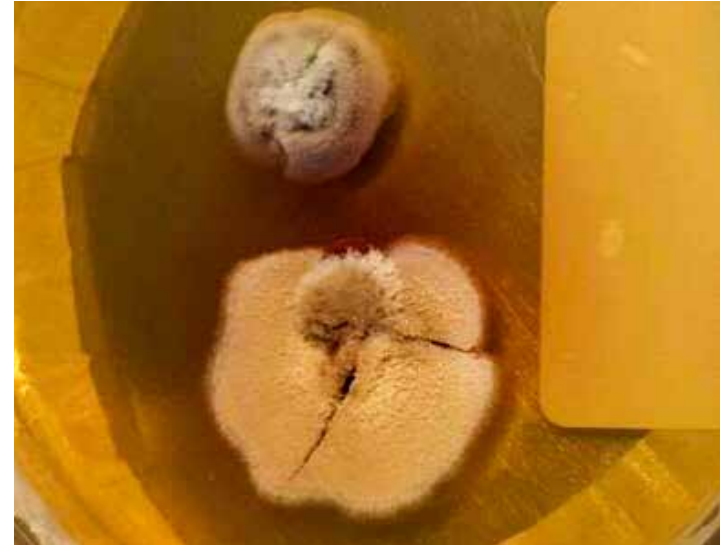
On microscopy, septate hyphae are seen. Conidiophores can be of variable length and branched and unbranched. Conidia are single-celled and club-shaped and grow directly along the hyphae or on the conidiophore. Intercalary cylindrical conidia are occasionally seen. (x10)

### Scopulariopsis species

*Scopulariopsis* is a common filamentous fungus found indoors in carpets, flooring, cellulose structures and swimming pools. It can cause a range of diseases from superficial infection such as onychomycosis to locally invasive soft tissue infections and disseminated disease in immunosuppressed patients. *Scopulariopsis* produces conidiophores that closely resemble that of *Penicillium* species.

*Scopulariopsis* spp., front view on SDA

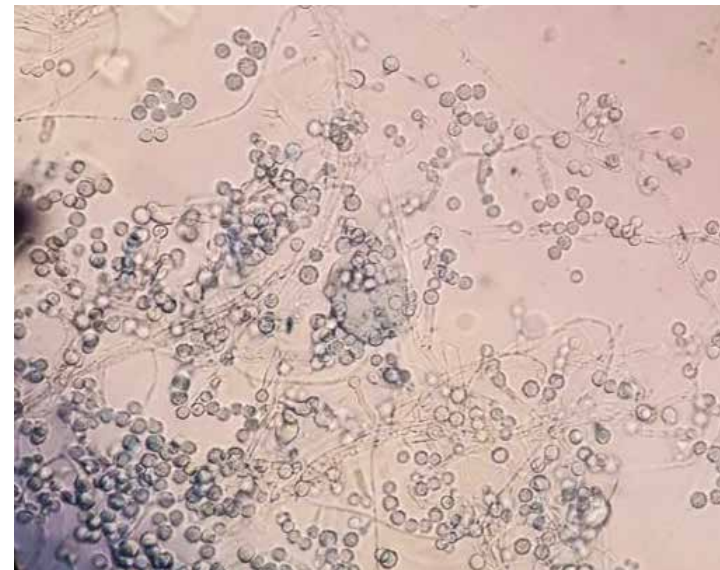
Fig. 3.5-21



Rapid growing colony that matures in 5 days. Colonies are initially white but turn light brown (sandy brown) on standing. On reverse, colonies are powdery with a tan colour.

*Scopulariopsis* spp., LPCB wet mount preparation

Fig. 3.5-22



Septate hyphae with short conidiophores terminating in branched heads with cells that are swollen at base and narrow at apex. These cells bear chains of lemon-shaped, rough and thick-walled conidia with a flattened base. (x40)

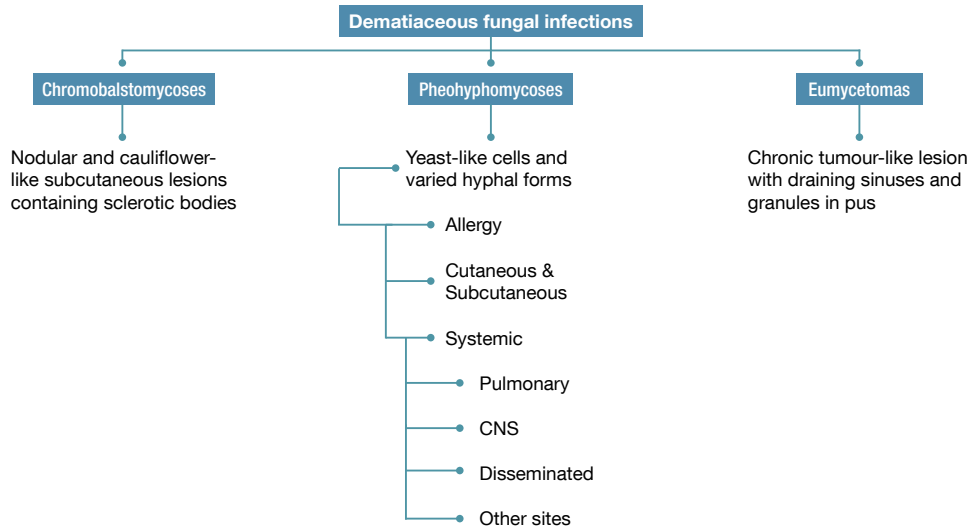
## Dematiaceous Molds and Melanised Fungi

Joveria Farooqi and Kauser Jabeen

Dematiaceous fungi are a group of fungi with melanin in their cell walls. Being environmental fungi, their sources are plant materials and soil. Most lesions arise due to traumatic implantation or inhalation and deep mycoses result either from haematogenous dissemination or contiguous invasion.

Lesions may be divided into three main categories on the basis of morphology and histopathological features:

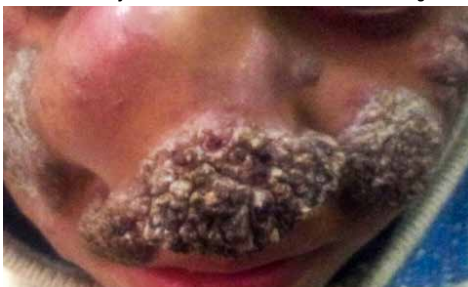- **Chromoblastomycoses** are pathognomically characterised by the presence of rounded copper-coloured structures with cross-walls called sclerotic bodies and cause nodular and cauliflower-like subcutaneous lesions.
- **Pheohyphomycoses** are characterised by moniliform and toruloid (yeast-like) hyphae which may be cutaneous, subcutaneous or deep lesions e.g. cerebral, pulmonary, bone or spinal abscesses.
- **Eumycetomas** usually involve exposed areas of the body and are distorted nodular lesions giving rise to draining sinuses with granules. Granules are frequently dark coloured, and microscopically show hyphal forms.



### Clinical Presentation

Chromoblastomycosis

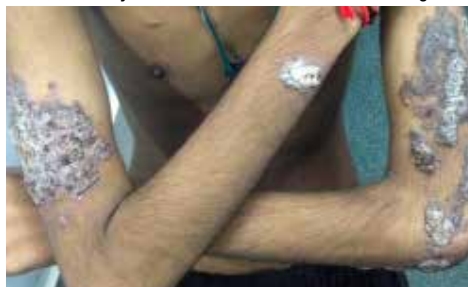Fig. 3.6-1



Nodular subcutaneous lesions with cauliflower-like outgrowths on exposed areas of the body (hands, feet and face).

Chromoblastomycosis

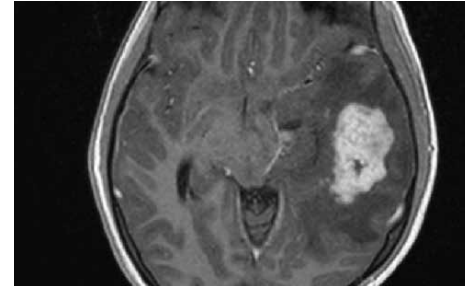
Fig. 3.6-2



Nodular subcutaneous lesions with cauliflower-like outgrowths on exposed areas of the body (hands, feet and face).

Phaeohyphomycosis

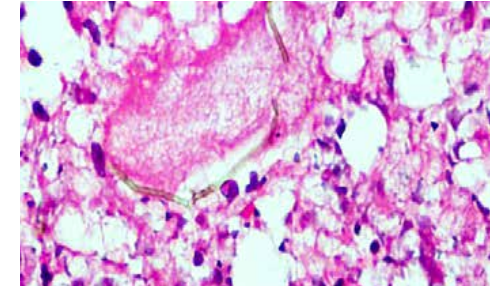
Fig. 3.6-3



Deep phaeohyphomycoses present as abscesses involving one or several organs. This is an image of a large brain abscess due to *Neoscytalidium* species.

Phaeohyphomycosis, H&E stain

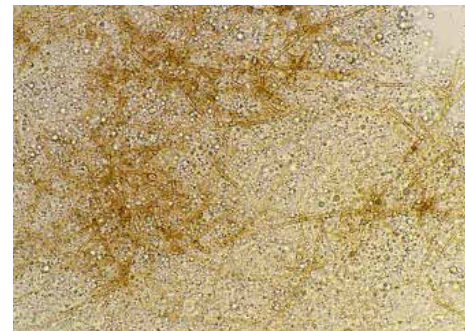
Fig. 3.6-4



Biopsy of a brain abscess shows golden brown septate hyphae. (x40)

Phaeohyphomycosis, 10% KOH wet mount

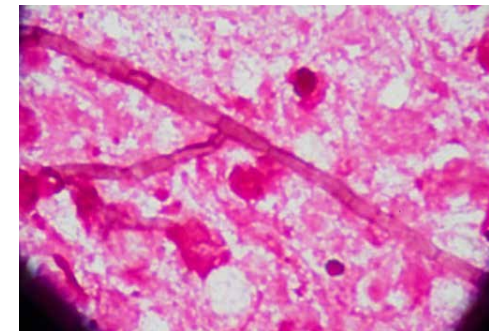
Fig. 3.6-5



Smear from patient with brain abscess shows numerous pigmented hyphae. (x10)

Phaeohyphomycosis, Gram stain

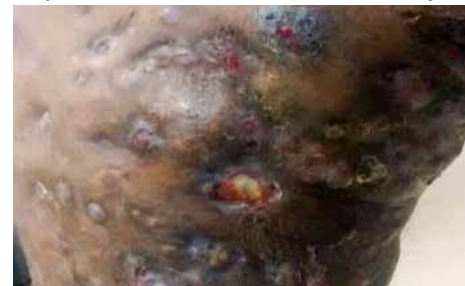Fig. 3.6-6



Stain sample from a patient with brain abscess shows pigmented septate hyphae. (x100)

Eumycetoma

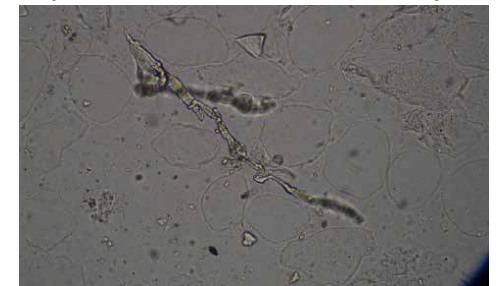
Fig. 3.6-7



The lesions are characteristically situated in exposed body parts. They are deeply penetrating infections resulting in sinus formation and hardening of surrounding tissue. The pus draining from the sinuses shows granules which may be pigmented (melanised fungi), whitish (aerobic *Actinomyces* such as *Nocardia*) or yellow (*Actinomyces*).

Eumycetoma, 10% KOH wet mount smear

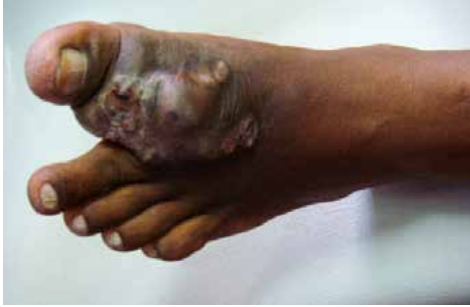Fig. 3.6-8



Mount of a eumycetoma granule showing distorted septate hyphae which may themselves be pigmented or secreting a dark pigment into the surrounding tissue. (x40)

Madura (mycetoma) foot

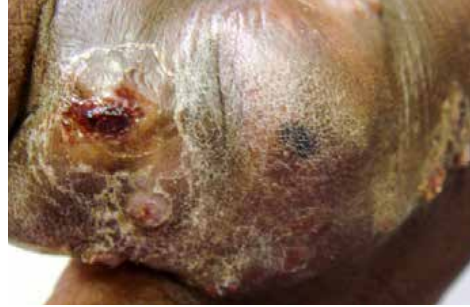Fig. 3.6-9



Patient presented with a 1-year history of slowly enlarging painless nodules on foot after minor trauma. Later these papules and pustules formed draining sinuses discharging grains.

A close-up view of mycetoma foot

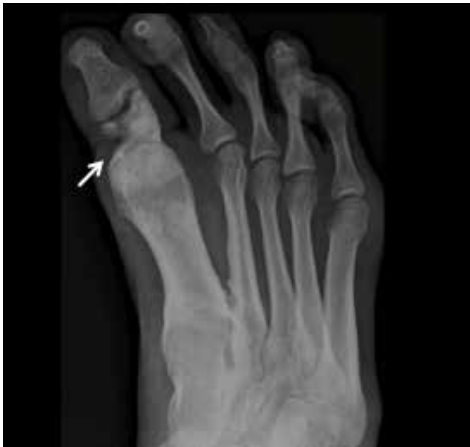Fig. 3.6-10



The infection can permanently scar and damage skin, subcutaneous tissues and bones. This patient was treated with debulking and reconstructive surgery by a plastic surgeon combined with itraconazole and rifampicin therapy for 2 years.

Fungal osteomyelitis and arthritis

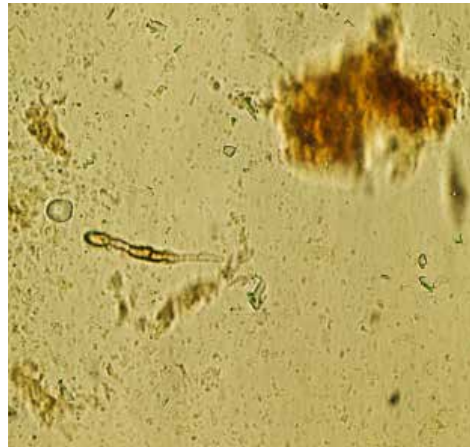Fig. 3.6-11



A 20-year-old patient presented with a swollen and discharging sinus over the medial side of right foot. Radiograph shows a soft tissue swelling overlying the big toe along with sclerosis and destruction of the proximal phalanx as well as the metatarsophalangeal joint (arrow). The appearances are consistent with fungal osteomyelitis and arthritis.

Fungal osteomyelitis and arthritis, 10% KOH wet mount smear

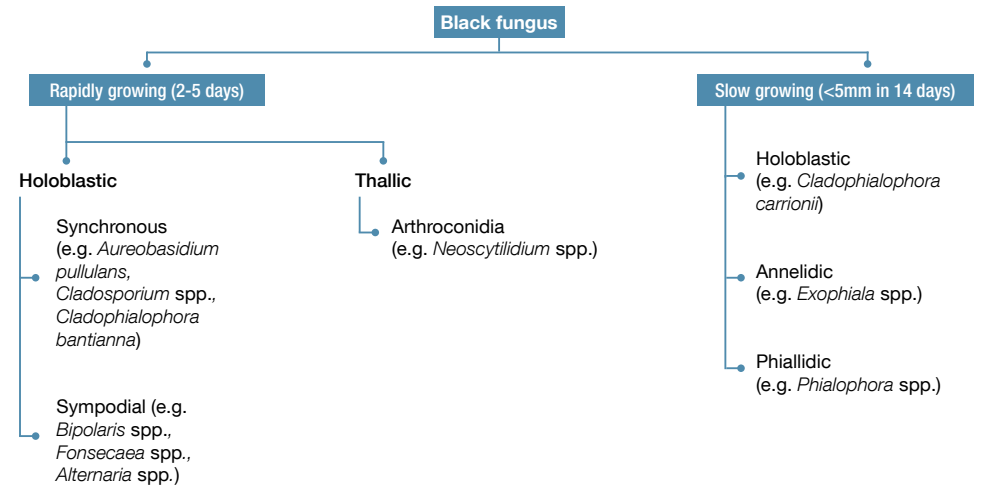
Fig. 3.6-12



Septate hyphae in tissue from the patient with mycetoma. (x40)

**Identification**

- Dematiaceous molds are differentiated based on the rates of growth (slow growing versus rapidly growing) and then further divided based on the origin of conidia:
  - Holoblastic: conidia arise with all layers of cell wall from conidiophores.
  - Enteroblastic: conidia arise from internal layer of conidiophore by bursting out of the outer cell wall.
  - Thallic: conidia form by breaking off from the main hyphae after lysis of the separating cells.
- Common dematiaceous fungi can be identified using the simple schema shown.



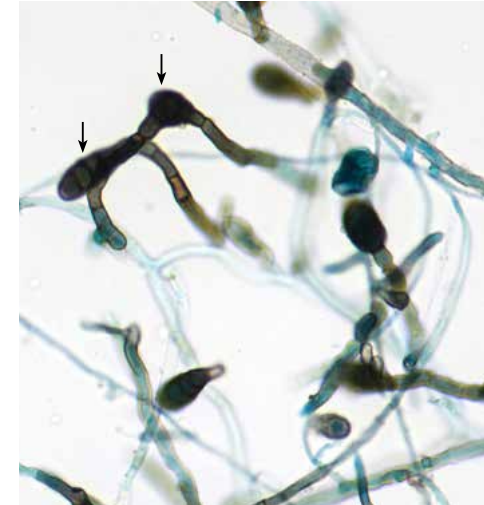
**Alternaria species**

*Alternaria* is one of the most common rapidly growing black molds found in the environment and soil. It is frequently isolated from fungal polyps, sputum samples, nails of patients with onychomycosis and other infections due to traumatic implantation e.g. keratitis, soft tissue infections and even brain abscesses.

Culture on SDA leads to rapidly growing colonies (>5 mm in 5 days) that are olivaceous green at the front and black on reverse side (not shown). Initially, colonies are flat and then become fluffy with a white downy border.

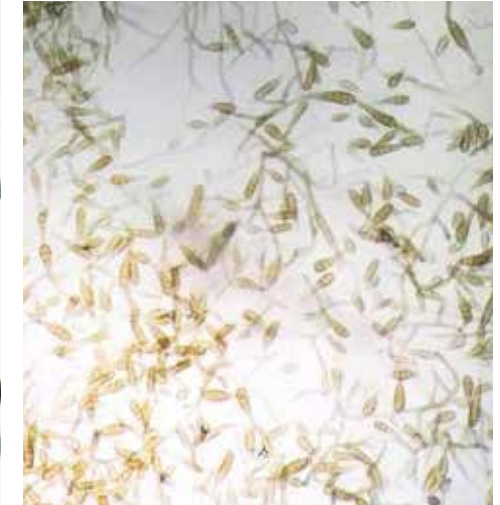*Alternaria* spp., LPCB wet mount preparation

Fig. 3.6-13



Muriform elongated conidia of *Alternaria* spp. in chains (using objective lens x10)

Fig. 3.6-14



Microscopically, the tapering conidia arise in chains and have both transverse and vertical septae giving a muriform appearance. The conidiation is considered sympodial as conidia arising from the same conidiophore are seen in various stages of development. (x40), (x10) (see arrow)

### *Bipolaris* and *Drechslera* species

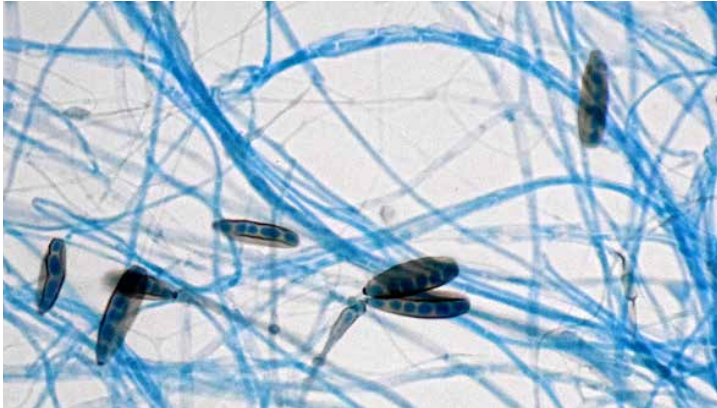Rapidly growing black molds found in the environment. Similar to *Alternaria* species in clinical relevance, they are commonly isolated from nasal sinuses, respiratory specimens and wounds contaminated with environmental debris. To differentiate between *Bipolaris* and *Drechslera*, perform the germ tube test and observe germination of the hyphae from the hilum:

- *Bipolaris* – germ tubes arise along the long axis of the conidia.
- *Drechslera* – germ tubes arise at right angle to the long axis of the conidia.

Both show fluffy colonies with olivaceous black surface on the front and a dark brown tinge on reverse side (not shown).

*Bipolaris* spp., LPCB wet mount preparation

Fig. 3.6-15



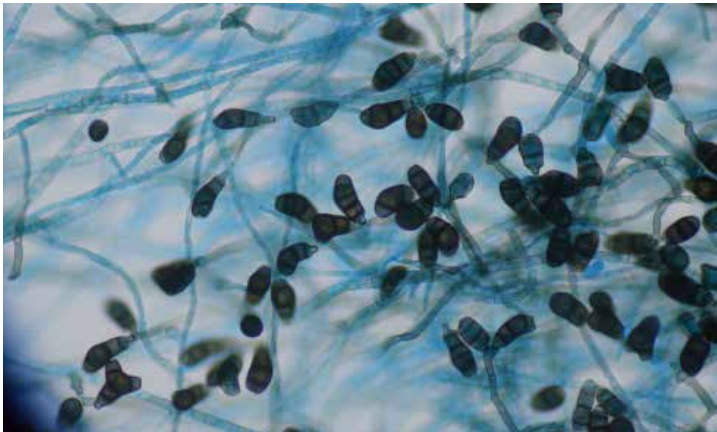
Microscopically, they both have elongated conidia with transverse septae with 3-6 cells. Conidia are holoblastic and sympodial. *Bipolaris* species have more abundant conidia arising at the tips of conidiophores along their long axis while *Drechslera* species have fewer conidia arising at right angles to the conidiophores. (x40)

### *Curvularia* species

*Curvularia* is a saprophytic rapidly-growing black mold with similar distribution to *Alternaria*, *Drechslera* and *Bipolaris* spp. Human infections with *Curvularia* spp. are rare, but can lead to fatal cerebral disease. Colonies are fluffy in texture and appear a deep black both on front and reverse, giving off a bluish hue as they age (not shown).

*Curvularia* spp., LPCB wet mount preparation

Fig. 3.6-16



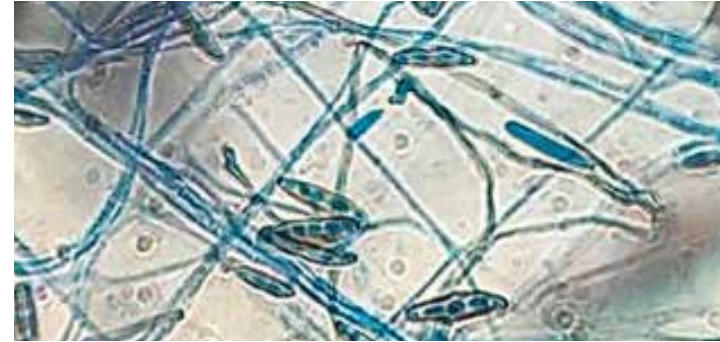The thallus consists of dark septate hyphae with conidia arising sympodially from the conidiophore. Conidia have transverse septae with 3-5 cells. Identifying characteristic is a large and darker central cell due to which the conidia appear curved or geniculate (like a bent knee). (x40)

### *Exserohilum* species

A rapidly growing black mold, *Exserohilum* gained fame during the 2012 iatrogenic fungal meningitis outbreak when a batch of epidural steroid injections was found to be contaminated with its spores. Clinical niche otherwise is similar to other saprophytic melanised fungi with sinusitis as the main manifestation. Colonies have fluffy grey surface on front and a dark reverse side (not shown).

*Exserohilum* spp., LPCB wet mount preparation

Fig. 3.6-17



Hyphae are septate and pigmented. Holoblastic conidiation gives rise to elongated conidia with 8-12 cells divided by transverse walls and ending in a prominent hilum. (x40)

### *Cladosporium* species

*Cladosporium* is an environmental contaminant that can cause serious disseminated haematogenous infections. Colonies grow slowly and mature within 3 weeks. Colour of colonies varies from dark grey, grey green to dark green on front, and appears black on reverse surface (not shown). A distinctive feature is the species inability to grow at temperatures above 37°C.

*Cladosporium* spp., LPCB wet mount preparation

Fig. 3.6-18



On microscopy hyphae are dark and septate, conidiophore have medium to long chains of conidia. Conidia are brown, smooth, oval with scar of attachment. Maximum growth temperature of the colonies is 35-37°C. Conidia are holoblastic and can be dislodged easily and resemble shields. (x40)

### *Cladophialophora* species

*Cladophialophora* is a mold that is an environmental contaminant and can cause serious disseminated hematogenous infections.

#### *Cladophialophora bantiana*

*C. bantiana* has a tropism for central nervous system and infection results in brain abscess. Colonies growth rate is slow and mature in 2 weeks. Colour of colonies varies from olive green to brown to black; reverse is black (not shown). The distinct feature of this species is thermotolerance and ability to grow at 42°C. On microscopy dark septate hyphae are seen. Conidiophores are long with unbranched chains of pale brown, oval conidia (not shown). No scar of attachment is seen in conidia.

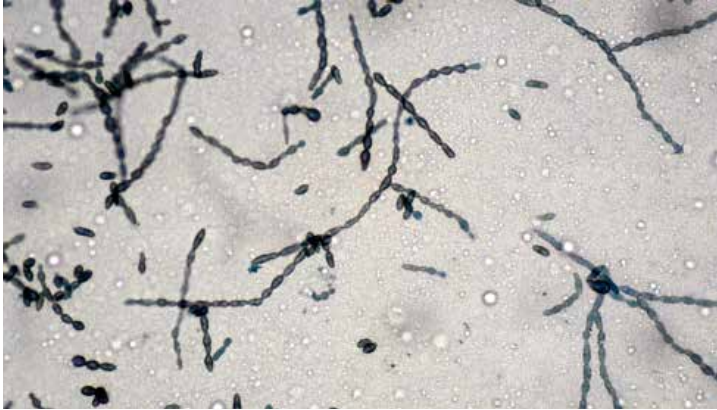**CAUTION:** *C. bantiana* is a Hazard Group 3 pathogen and can be transmitted to health care workers through respiratory route. Colonies should be handled in a biosafety cabinet and slide cultures should not be performed.

#### *Cladophialophora carrionii*

*C. carrionii* mainly causes chromoblastomycosis. Colonies grow slowly and mature within 3 weeks. Colour of colonies varies from dark grey, grey green to dark green with a black reverse (not shown). Maximum growth temperature of the colonies is 35-37°C.

*C. carrionii*, LPCB wet mount preparation

Fig. 3.6-19



Dark septate hyphae are seen. Conidiophores have medium length chains branching after 10-15 conidia. Conidia are brown, smooth, and oval with scar of attachment. (x40)

#### *Sporothrix schenckii*

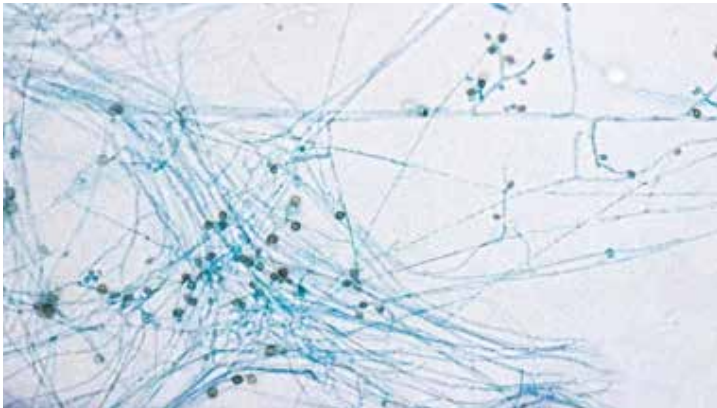
*S. schenckii* is a dimorphic fungus with a global distribution as an environmental contaminant. It is a known agent of sporotrichosis, a subcutaneous fungal infection that may involve lymphatic vessels, lymph nodes, bones and joints, as well as disseminated infection in immunosuppressed patients.

Colonies grow rapidly and mature in 5-7 days. Characteristics vary depending on incubation temperature:

- At 25-30°C initial colonies are white to grey that become black with age with a grey to black reverse. Colonies can be flat, leathery or wrinkled (not shown).
- At 35-37°C colonies are cream and yeast-like and may require repeated subcultures to obtain good yeast phase (not shown). Sometimes conversion to yeast form is incomplete and therefore an inhibited and slower growth similar to that at 25-30°C is seen.

*S. schenckii*, LPCB wet mount preparation

Fig. 3.6-20



On microscopy hyaline, septate hyphae with delicate conidiophore are seen. Conidia are oval and appear on the apex of conidiophore in a rosette-like or star-like pattern. Later developed conidia are dark and develop singly along the hyphae. Microscopy of yeast form exhibits round, oval or cigar-shaped yeast cells. (x10)

#### *Exophiala* species

*Exophiala* is a slow-growing anellidic fungus found in decaying wood and soil. Common cause of subcutaneous infections and cerebral mycosis.

*Exophiala* spp., front view of culture on SDA agar

Fig. 3.6-21



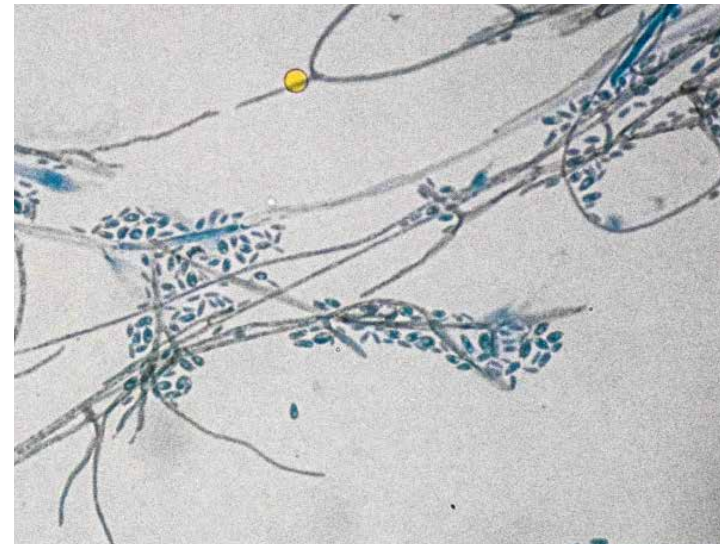
Young cultures show yeast-like appearance that convert to mold form with time.

#### *Exophiala jeanselmei*

Colonies are olive green to greenish black to black with a black reverse (not shown). Maximum growth temperature is 37°C. Does not grow at higher temperature. Matures in 2 weeks.

*E. jeanselmei*, LPCB wet mount preparation

Fig. 3.6-22



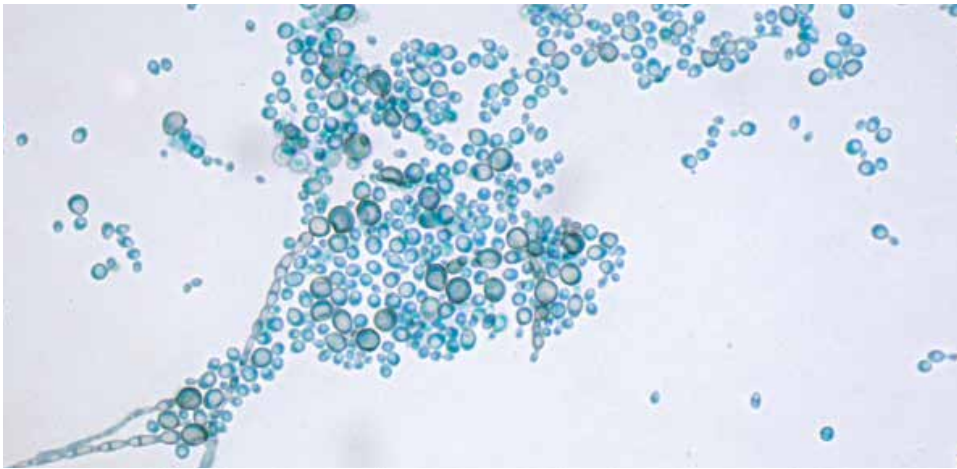
Septate hyphae with conidiophores, which are cylindrical with needle-like projections. Numerous brownish conidia that accumulate in groups at the tips of conidiophores or along the hyphae. (x10)

***Exophiala dermatitidis***

On culture, colonies are olive grey to greyish black with a dark reverse. May have a diffusible brown pigment. Maximum growth temperature is 42°C and maturity takes 3-4 weeks (not shown).

*E. dermatitidis*, LPCB wet mount preparation

Fig. 3.6-23



Abundant budding yeast like cells with few septate hyphae with conidiophores that are flask-shaped and lack a collarette. Few brownish conidia are seen that accumulate in groups at the apex or down the sides of conidiophores or along the hyphae. (x10)

***Fonsecaea pedrosoi***

*F. pedrosoi* is the most common cause of chromoblastomycosis worldwide. Single isolate may have two to three types of conidiation.

Conidiation types includes *Fonsecaea* type (conidiophore: erect, septate and sympodial with distal end swollen; conidia: single-celled; long chains: not formed); *Rhinocladiella* type (conidiophore: erect, septate and sympodial with distal end swollen; conidia: single-celled either on the distal end of conidiophore or along the side); *Cladosporium* type (conidiophore: erect; conidia: scarred and in short chains; shield cells seen); and *Phialophora* type (vase-shaped phialides with terminal collarettes having oval conidia).

*F. pedrosoi*, front view of culture on SDA

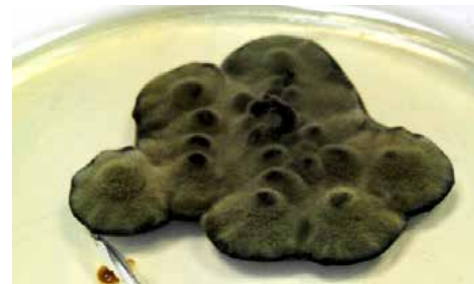Fig. 3.6-24

*F. pedrosoi*, front view of culture on SDA

Fig. 3.6-25



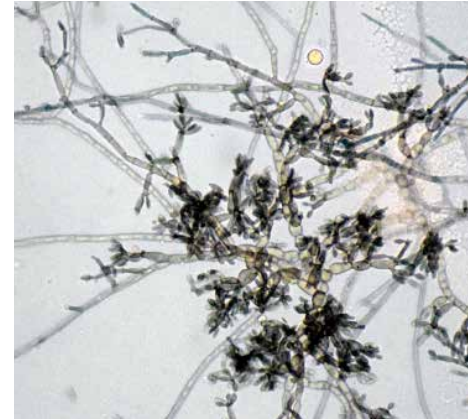
Day 5. Colonies are dark green, grey or black, flat and velvety. Reverse view is black. Culture on SDA shows colonies that grow slowly and mature in around 14 days.



Day 15. Colonies are slow growing.

*F. pedrosoi*, LPCB wet mount preparation

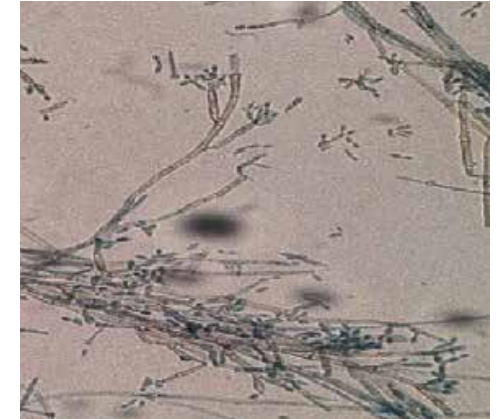
Fig. 3.6-26



Pigmented hyphae with dark conidia. Single isolate may have two to three types of conidiation. In this slide, *fonsecaea*, *rhinocladiella* and *Cladosporium* conidiation are seen. (x40)

*F. pedrosoi*, LPCB wet mount preparation

Fig. 3.6-27



Close-up view shows *fonsecaea* conidia. (x40)

***Rhinocladiella mackenziei***

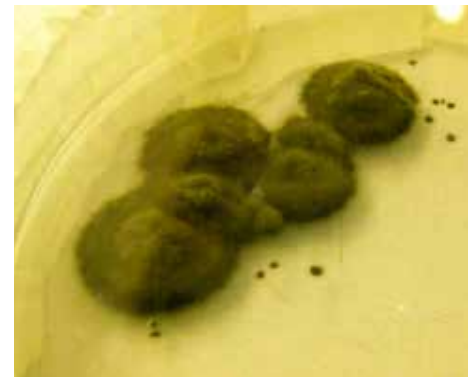*R. mackenziei* is a mold commonly found in arid regions of Middle East, Afghanistan, Pakistan and India. The majority of infections occur in immunocompetent individuals. In Pakistan, *R. mackenziei* has been as an agent of cerebral phaeohyphomycosis, which has an extremely low survival rate.

*R. mackenziei*, front view of culture on SDA

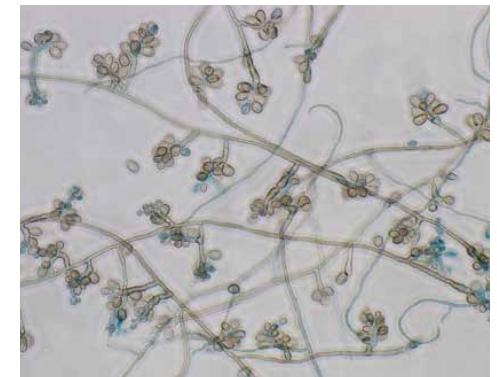Fig. 3.6-28

*R. mackenziei*, LPCB wet mount preparation

Fig. 3.6-29



Growth is dark grey-brown to black. Colonies are slow growing and mature in 3-4 weeks. Some isolates do not grow up to 4 weeks and grow initially as black discolouration of media. Reverse is black.



On microscopy, hyphae are pigmented, septate with dark brown oval conidia. Conidiation is poor on first isolation and develops later after subsequent subcultures. The characteristic diagnostic feature is the *Rhinocladiella* type sporulation that gives the "mickey mouse appearance": multiple budding with thick-walled cells. This is not seen with any other type of sporulation even after prolonged incubation. (x40)

Fig. 3.5.2-28 Copyright © Oxford University Press, [Clinical Infectious Diseases 52, 2011, 213-217, doi: 10.1093/cid/ciq114]  
 Fig. 3.5.2-29 Copyright © Oxford University Press, [Clinical Infectious Diseases 52, 2011, 213-217, doi: 10.1093/cid/ciq114]

### Neoscytalidium dimidiatum

Mold commonly found in tropical and subtropical region environments, causing infection secondary to trauma. Results in dermatomycosis, onychomycosis and, very rarely, systemic infections.

*N. dimidiatum*, front view of culture on SDA Fig. 3.6-30 *N. dimidiatum*, LPCB wet mount preparation Fig. 3.6-31



Colonies grow fast and mature in 3 days. Surface is initially white but rapidly changes to dark brown or black. Reverse is black. Woolly in texture and may fill the air space of the culture plate.

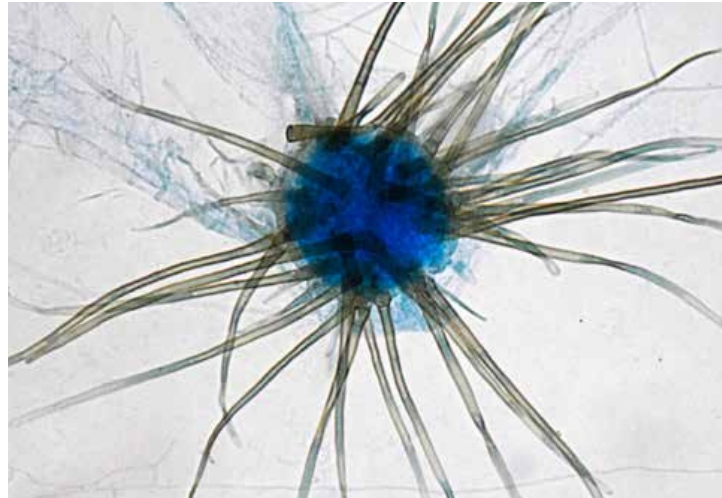
Septate hyphae without conidiophore are seen. Dark brown wider and hyaline narrow arthrospores are seen in abundance. These arthroconidia are either one-celled or two-celled separated by a thick septum. Shape of arthrospores varies from rectangle, square, oval, or barrel shaped. There are no empty cells between consecutive arthrospores. (x40)

### Chaetomium species

*Chaetomium* is a mold found in environment particularly water-damaged buildings and can result in serious life-threatening systemic infections.

On culture, colonies grow fast and mature within 3-5 days. On front, initially colonies are white but with aging turn pale buff, olive green and then greyish green. Reverse is buff (may be brown to black) with sometimes a green, yellow or red diffusible pigment (not shown).

Close-up view of an ascocarp, LPCB wet mount preparation Fig. 3.6-32

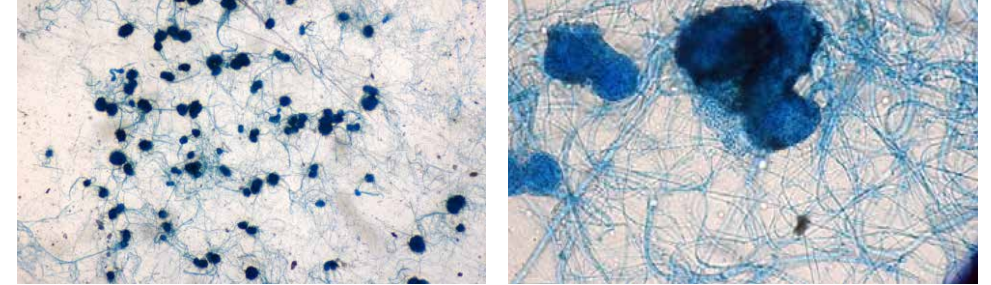


Ascocarp is a large brown oval structure with unbranched wavy and dark-coloured hyphae radiating from it. They contain asci that are club-shaped and contain 4-8 spores. Ascospores are lemon-shaped, brown and single-celled. (x40)

### Phoma species

*Phoma* species is typically an environmental contaminant causing infections in plants but can cause rare fatal disseminated fungal infections in humans. On culture on SDA, colonies are fast-growing and mature within 3-5 days. On gross examination, colonies are reddish to greyish brown on front and brown to black on reverse (not shown). Sometimes a reddish brown diffusible pigment is seen.

*Phoma* spp., LPCB wet mount preparation Fig. 3.6-33 Close-up view of ostiole, LPCB wet mount preparation Fig. 3.6-34



On microscopy, septate hyphae are seen. A prominent feature is the presence of large pycnidia or fruiting bodies that are dark and oval to round with an opening called ostiole. (x40)

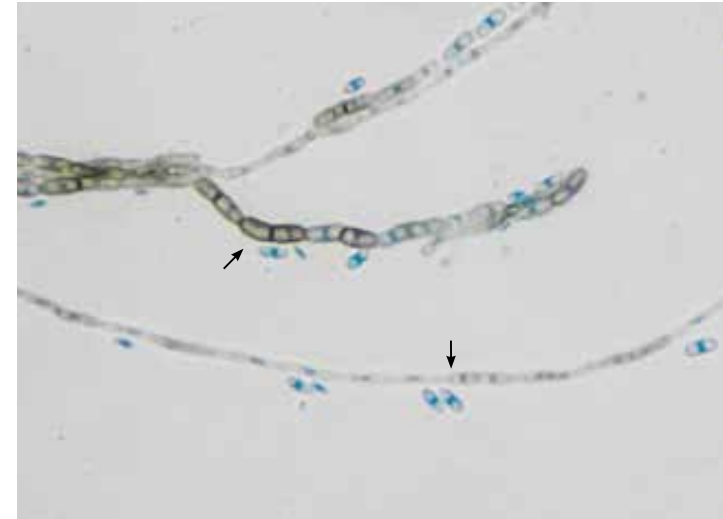
Through this opening, colourless ovoid single-celled conidia are released. (x100)

### Hormonema dematioides

*H. dematioides* is a yeast-like fungus found in environment that causes rare but clinically-significant infection in immunosuppressed patients.

On culture on SDA, colonies mature rapidly in 3-5 days. Initial colonies are buff and smooth with a pink tinge (not shown). On extended incubation, colonies are brownish black on front and black on reverse.

*H. dematioides*, LPCB wet mount preparation Fig. 3.6-35



On microscopy young colonies have abundant yeast-like cells. Microscopy of older colonies exhibit two types of hyphae:

- hyaline and thin-walled with conidia arising directly, and
- dark and thick-walled that break into arthroconidia. The pigmented hyphae also bear conidia. (x40)

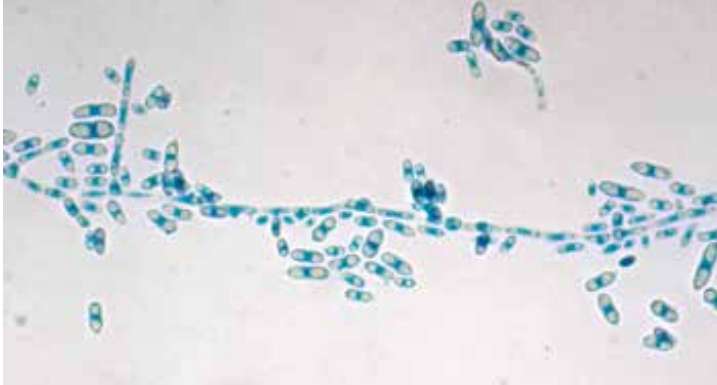
*Phaeoannellomyces werneckii*

Also known as *Hortaea werneckii*, this fungus is found in soil, compost and wood, and is a causative agent of tinea nigra.

On culture, colonies are slow growing and can take up to 3 weeks to mature. Initial colonies are yeast-like. Growth on front is olive-black and black on reverse (not shown).

*P. werneckii*, LPCB wet mount preparation

Fig. 3.6-36



Microscopy of young colonies reveals pale or dark brown yeast-like cells with a central septum. These cells are pointed at one end and rounded at the other end. Older colonies develop septate hyphae with thick brown walls. (x10)

*Madurella species*

*Madurella* is a common soil fungus found in tropical regions and causes infections secondary to trauma. Infection results in mycetomas localised to cutaneous and subcutaneous tissues, fascia and bone. On culture, colonies are slow growing and may take up to 14 days to mature.

*Madurella mycetomatis*

Culture on SDA produces colonies that are cream, yellow to olive brown in front, and on reverse brown with a diffusible pigment (not shown). On microscopic examination, septate hyphae are visible that are usually sterile. At times, culture on CMT agar produces phialides that bear small oval to round conidia (not shown).

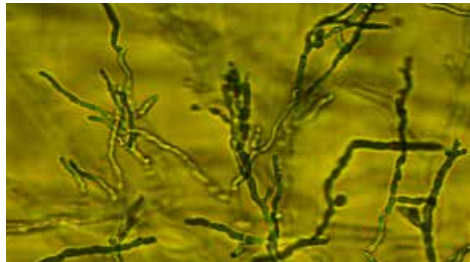
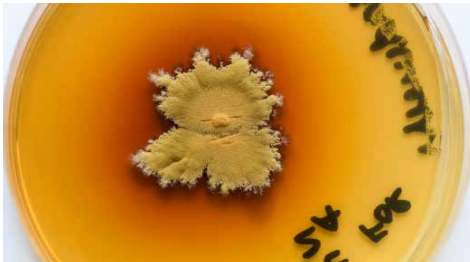*Madurella grisea*

*M. grisea*, front view of culture on SDA

Fig. 3.6-37

*M. grisea*, microscopic examination

Fig. 3.6-38



Colonies are folded and dark brown to black. On reverse, colonies are dark. A diffusible pigment may be seen. Colonies do not grow at 37°C.

Dark and wide septate hyphae. The hyphae are made of chains of round cells. Apart from these hyphae, thinner septate hyphae are also seen. These hyphae are usually sterile. Chlamydoconidia are rarely produced. (x40)

ANTIFUNGAL  
SUSCEPTIBILITY  
TESTING

## Antifungal Susceptibility Testing

Joveria Farooqi

Improvements in diagnostic tools have allowed an increasing number of invasive fungal infections to be diagnosed and treated with antimicrobials. At the same time, resistance to antifungals has emerged as a significant problem. Susceptibility to antifungals is well-studied for the yeast form with established clinical breakpoints.

In the clinical setting, three main families of antimycotics are used to treat infections: polyenes (amphotericin B, nystatin and natamycin); azoles (itraconazole, fluconazole, voriconazole, posaconazole and isavuconazole); and echinocandins (casposfungin, micafungin and anidulafungin).

Currently, standardised methodology for susceptibility is available for *Candida* species, *Cryptococcus* species, and non-dermatophyte molds. However, clinical breakpoints are available for only certain *Candida* species and have not yet been established for *Cryptococcus* species and molds. Susceptibility testing for yeasts can be incorporated in clinical reporting as its performance is no more difficult than that of bacteria. Maintaining sterility during testing and quality control for molds, on the other hand, are much more exacting tasks than for yeasts.

### Susceptibility Testing for *Candida* species

In this chapter we have opted to solely focus on the methods to determine antifungal susceptibility against the *Candida* species considering the availability of definitive data — both CLSI and EUCAST have standardised disc diffusion and broth microdilution methodologies and breakpoints (clinical or epidemiological cut-offs).

#### Disc Diffusion Method

On an agar plate, colonies of fungal isolate are tested against antifungals. Clear zones around each disk (zones of inhibition) are measured to determine susceptibility and MICs.

#### Prerequisites

- Müller-Hinton agar plate supplemented with 0.5 µg/ml methylene blue and 2% dextrose.
- Glass tube with 0.85% sterile saline solution.
- Isolated yeast colonies from a 20-24 hours old culture grown on an antibiotic-free medium (SBA, SDA or PDA).

#### Procedure

- Make a suspension of 0.5 McFarland turbidity in 0.85% saline with a few colonies from a 20-24 hours old culture of *Candida* species on an antibiotic-free medium.
- Soak a sterile cotton swab in the suspension, rolling it along the glass wall of the tube to get rid of the excess moisture.
- Make lawn on MHA supplemented with methylene blue and 2% dextrose.
- Using sterile forceps place antifungal discs on the agar surface and incubate the plates at 35±1°C for 20-24 hours in ambient air.
- Measure zone diameters for each antifungal:
  - For azoles measure zones from where there is 50-80% inhibition of growth.
  - For casposfungin measure zones from where there is complete inhibition of growth.
- Interpret readings according to the specific *Candida* species (Table 4.1).
- Compare with QC ranges for the recommended ATCC strains (Table 4.2).

### Minimum Inhibitory Concentration Method – E-test

A plastic strip is impregnated with gradually decreasing concentration of a particular antibiotic. The method is convenient but costly since a new strip is needed for each antibiotic. Breakpoints of broth microdilution method are applied, although not yet approved for E-test.

#### Prerequisites

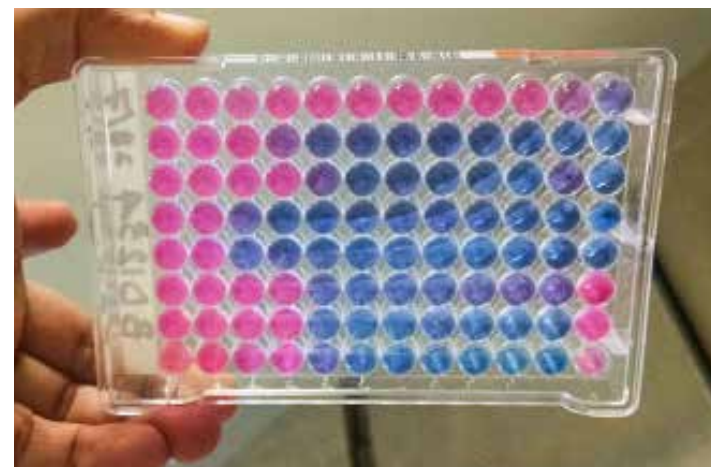- RPMI agar with phenol red and 2% dextrose. For RPMI media preparation, refer to EUCAST guidelines on antifungal susceptibility testing.
- Glass tube with 0.85% sterile saline solution.
- Isolated yeast colonies from a 20-24 hours old culture grown on an antibiotic-free medium (SBA, SDA or PDA).

#### Procedure

- Make a suspension of 0.5 McFarland turbidity with a few colonies from a 20-24 hours old culture of *Candida* species on an antibiotic-free medium in 0.85% saline.
- Soak a sterile cotton swab in the suspension, rolling it along the glass wall of the tube to get rid of excess moisture.
- Make lawn on RPMI agar.
- Use sterile forceps to place E-test strips on the surface of the agar taking care not to move the strip and ensuring there are no air bubbles between the strip and the agar surface.
- Incubate the plates at 35±1°C for 20-24 hours in ambient air.
- For azoles measure MICs where there is 50-80% inhibition of growth.
- For amphotericin B and echinocandins measure MICs where there is complete inhibition of growth.
- Interpret readings according to specific *Candida* species (Table 4.1).
- Compare with QC ranges for the recommended ATCC strains (Table 4.2).

### Minimum Inhibitory Concentration Method – Broth Microdilution

This is considered gold standard in antifungal susceptibility testing. Detailed methodology is beyond the scope of this book but is available in CLSI M24-A4 and EUCAST (online). Commercial variations of the conventional broth microdilution method are also available from various manufacturers. These products are user-friendly and results are comparable to the standard method.



**Fig. 4.1: Commercially available colourimetric broth microdilution assay, YeastOne Sensititre®, for antifungal susceptibility testing of *Candida* and *Cryptococcus* species. Growth of yeast in the wells changes the colour of alamar blue to pink, making MIC reading easier.**

**Table 4.1: Interpretation of zone diameters and minimal inhibitory concentration according to CLSI**

Species	Antifungal	Susceptible		Susceptible dose-dependent/ intermediate		Resistant		Non-susceptible	
		ZD (mm)	MIC (µg/ml)	ZD (mm)	MIC (µg/ml)	ZD (mm)	MIC (µg/ml)	ZD (mm)	MIC (µg/ml)
<i>C. albicans</i> <i>C. tropicalis</i> <i>C. parapsilosis</i>	Fluconazole 25µg	≥19	≤2	15-18	4	≤14	≥8	-	-
	Voriconazole 1µg	≥17	≤0.12	14-16	0.25-0.5	≤13	≥1	-	-
	Caspofungin 5µg	≥11	≤0.25	-	0.5	-	-	<11	≥1
<i>C. parapsilosis</i> <i>C. guilliermondii</i>		-	≤2	-	4	-	8	-	-
<i>C. glabrata</i>	Fluconazole 25µg	-	-	≥15	≤32	≤14	≥64	-	-
	Voriconazole 1µg	≥17	≤1	14-16	-	≤13	>1	-	-
	Caspofungin 5µg	≥11	≤0.12	-	0.25	-	-	<11	≥0.5
<i>C. krusei</i> †	Caspofungin 5µg	≥11	≤0.25	-	0.5	-	-	<11	≥1
	Voriconazole 1µg	≥17	≤0.5	14-16	1	≤13	≥2	-	-
All species	Fluconazole 25µg	≥19	≤8	15-18	16-32	≤14	≥64	-	-
	Voriconazole 1µg	≥17	≤1	14-16	2	≤13	≥4	-	-
	Caspofungin 5µg *	≥11	≤2	-	-	-	-	<11	>2
	Amphotericin10µg^	-	≤1	-	-	-	-	-	≥2

†Do not report fluconazole for *C. krusei* due to inherent resistance. \*All species except for *C. parapsilosis* and *C. guilliermondii*. ^*C.lusitaniae* rapidly develops resistance to amphotericin B on therapy; do not report for *C. lusitaniae*.

**Table 4.2: Quality control ranges for yeast susceptibility testing**

Perform quality control every time a new batch of Müller-Hinton agar with methylene blue or RPMI agar is made.

Organism	Antifungal (disc content in µg)	MIC range (µg/ml)	Zone diameter (mm)
<i>C. parapsilosis</i> ATCC 22019	Amphotericin B	0.25-2.0	-
	Fluconazole (25)	0.5-4.0	22-33
	Voriconazole (1)	0.016-0.12	28-37
	Itraconazole	0.12-0.5	-
	Caspofungin (5)	0.25-1.0-	14-23
<i>C. krusei</i> ATCC 6258	Amphotericin B	0.5-2.0	-
	Fluconazole	8.0-64.0	-
	Voriconazole (1)	0.06-0.5	16-25
	Itraconazole	0.12-1.0	-
	Caspofungin (5)	0.12-1.0	18-26



# 5 ANTIGEN-BASED TESTS FOR THE DIAGNOSIS OF FUNGAL INFECTIONS

## Antigen-based Tests for the Diagnosis of Fungal Infections

Kauser Jabeen and Joveria Farooqi

Several successful attempts have been made to use non-culture and non-invasive approaches to diagnose fungal infections. Tests are available that can detect specific fungal antigens, the host antibody generated and large macromolecules specific to fungal pathogens. Reliability of results depends on the the microbial burden, time of testing (early versus late in disease process), immunocompetency of the host and the presence of underlying diseases or co-infections. Results must always be carefully interpreted in light of sensitivity and specificity of each test.

### Cryptococcal Antigen Testing

This test is based on latex particle agglutination methodology. Latex particles labeled with antibodies specific to cryptococcal capsular antigen are mixed with patient specimens such as CSF and serum, and observed for any clumping.

#### Procedure

- Instructions in the insert should be followed precisely. As with handling all clinical specimens, gloves should be worn while performing the test.
- Working with CSF
  - a. Take at least 0.5 ml (preferably 1 ml) of CSF in a sterile glass tube and boil it for 5 minutes.
  - b. Allow to cool. Label the disposable mixing card.
  - c. Prepare a 1:100 dilution by taking 25  $\mu$ l of the heat-inactivated specimen and mixing with 2475  $\mu$ l of sterile normal saline.
  - d. In four separate wells on a slide, place 25  $\mu$ l of heat-inactivated specimen, 25  $\mu$ l of the 1:100 dilution, and 25  $\mu$ l of positive and negative controls. Then add 25  $\mu$ l of latex reagent in the four wells.
  - e. Mix well covering the entire reaction area and rotate at 100 rpm for 15 minutes.
  - f. Observe for agglutination (granularity), comparing it with positive and negative controls.
  - g. All positive test results should be doubly titrated and maximum titre showing agglutination reported.
- Working with serum
  - h. Add 300  $\mu$ l of serum to a labeled glass tube and mix with 50  $\mu$ l of pronase reactant, vortex and heat at 56°C for 30 minutes.
  - i. Follow steps b. to g. as above.

#### Interpretation

- Presence of clumping is indicative of the presence of cryptococcal antigen.

#### Errors

- False positives may occur with presence of silicone, glove latex, protein, *Capnocytophaga* species and yeasts such as *Trichosporon* species.
- False negatives may occur with inadequate extraction or prozone phenomenon.

### $\beta$ -D-Glucan Detection

The antigen (1 $\rightarrow$ 3)- $\beta$ -D-Glucan (BDG) is part of the fungal cell wall, not specific to any particular species. Its presence in serum indicates the release of the fungal cell wall antigen into the circulation, seen in invasive fungal infections. Detection of BDG concentration in serum is now established as one of the criteria for diagnosis of probable invasive mycoses.

#### Method

- An enzyme immunoassay (EIA) based technique is used to detect the antigen in patient samples, and methodology is according to manufacturer instructions.
- Samples must be obtained very carefully by venipuncture using talc-free gloves.
- BDG is a very sensitive test as laboratory based reagent deterioration or contamination from environmental spores can greatly affect results.
- It is advisable to run the test in triplicates before the performing technologist becomes proficient. Even for the most experienced technologist, the test must be run in duplicates at least.

#### Interpretation

- BDG cut-offs are well established for adults but not for paediatric patients as normal levels may be higher in children.
- Data for neonates and infants less than 6 months is lacking and therefore interpretation may be difficult.
- The site of infection, encapsulation and the amount of BDG produced by certain fungi may affect its serum concentration. The antigen test results will most likely be negative if the infection is due to low producers of BDG, like *Cryptococcus* spp., zygomycetes (including *Absidia* spp., *Mucor* spp. and *Rhizopus* spp) and *Blastomyces dermatitidis* in its yeast phase.
- If BDG levels fall in the indeterminate zone, additional testing is recommended after assessing the patient's risk of fungal disease. For high risk patients, sampling is recommended at least 2 to 3 times a week.

**Table 5.1:  $\beta$ -D-Glucan interpretative cut-offs**

Specimen	Breakpoint/cut-off
Serum	Negative <60 pg/ml Indeterminate 60-80 pg/ml (repeat test recommended), Positive >80 pg/ml

#### Errors

- False positive results may be seen in patients on haemodialysis, receiving albumin or immunoglobulins, on certain antibiotics, exposed to glucan-containing gauze or talc, and those with mucositis. BDG may be tested 3-4 days after the source has been removed.
- False negatives may be due to lipemic or hydrolysed blood samples (elevated triglycerides and bilirubin are inhibitory to the sample).

### Galactomannan Detection

Galactomannan (GM) is an antigen found in the cell wall of *Aspergillus* species. Its detection by EIA has been in use for over a decade now as a non-invasive method to improve diagnostic sensitivity of invasive aspergillosis (IA). The test should never be used alone to confirm IA, and it should be interpreted in conjunction with clinical, radiological and culture findings as well as patient risk stratification.

#### Method

- EIA technique is used to detect the presence of GM antigen in recommended patient specimens, such as serum, bronchial lavage and CSF.

### Interpretation

- An index of <0.5 is considered negative in all samples. However, galactomannan index (GMI) can also be used to assess response to therapy and rising or falling index may be interpreted as failure or response to therapy, respectively.
- A serum GMI value persistently >1.0 is considered a sign of therapeutic failure.

**Table 5.2: GMI interpretative cut-offs**

Specimen	Breakpoint/cut-off
Serum	A single serum sample with GMI >0.7, or 2 consecutive samples with GMI > 0.5
Bronchoalveolar lavage	GMI >1.0
CSF	GMI >0.5

### Errors

- False positives may be seen with laboratory contamination of water bath, ELISA plates or pipettes. Biological false positives may be seen with certain antibiotics (penicillins e.g. ampicillin, amoxicillin, amoxicillin-clavulanate, piperacillin-tazobactam) and bacteraemia.
- False negatives results are based on the extent of angio-invasion and dissemination as well as immunosuppressed state of the patient.



# MOLECULAR METHODS FOR THE DIAGNOSIS OF FUNGAL INFECTIONS

## Molecular Methods for the Diagnosis of Fungal Infections

Sadia Shakoor

Molecular approach to diagnostics is fast becoming the accepted standard for a number of bacterial and viral infections, especially for identification of isolates growing in pure cultures. Techniques used for identification include nucleic acid hybridisation probes, DNA sequencing, and peptide nucleic acid fluorescence in situ hybridisation (PNA-FISH). This chapter briefly describes the existing technologies for direct detection of fungal pathogens from clinical samples, their current status and prospects for further development.

### Current Status

Despite being around for more than a decade, no recommendations for the use of molecular methods in fungal diagnostics have been made in recent guidelines. Molecular techniques combined with mass spectrometry procedures is a promising emerging diagnostic tool for fungal and bacterial identification alike. Although in the early development and validation stage, it is hoped that this will overcome the challenges faced by other molecular tests for fungal identification. The most important factor precluding recommendations remains difficult standardisation of tests (Box 6.1). After addressing these, and development of accurate tests, the next required step is FDA approval or CE marking before tests can be clinically validated and recommended as standard-of-care.

Despite these hindrances to the widespread adaptation of fungal molecular diagnostics, several commercial tests are available and have been demonstrated to be useful in diagnosis of fungal infections.

#### Box 6.1: Challenges in development of accurate fungal molecular diagnostics tools

- Methods for fungal molecular diagnosis are not standardised
- Extraction methods differ
- Primers used differ
- Cut-offs used differ for quantitative real time PCR
- Results vary depending on optimal time of sampling
- Patients on treatment continue to show positive results; cannot be used for prognosis
- Potential for false positive results
- Fungi are common environmental contaminants
- Colonisation versus infection, needs quantitative cut-offs
- Co-colonisation and co-infection with other fungi may be common confounders

**Table 6.1: Molecular tests, sensitivities and specificities, and approval status**

Fungal infection	Test	Current status	Comments
Invasive Aspergillosis	Aspergillus real-time PCR	Not FDA approved but based on recommendations by European Aspergillus PCR Initiative (EAPCRI) and Aspergillus Technology Consortium, tests in clinical trials	<ul style="list-style-type: none"> <li>• In bronchial specimens, sensitivity ~80% (comparable to galactomannan) while specificity ~90%</li> <li>• Combined use with galactomannan and <math>\beta</math>-D-Glucan detection increases sensitivity</li> </ul>
Invasive Candidiasis	Candida real-time PCR (ITS1 for <i>Candida</i> spp.)	Not FDA approved	<ul style="list-style-type: none"> <li>• In plasma and serum samples, sensitivity &gt;90%</li> </ul>
	Yeast Traffic Light (PNA-FISH)	FDA approved	<ul style="list-style-type: none"> <li>• Used for blood culture bottle positive for yeasts</li> <li>• Can also differentiate between fluconazole resistant and susceptible species</li> </ul>
Mucormycosis	Real-time PCR	Early development, several different studies but no single standardised test	<ul style="list-style-type: none"> <li>• Used on blood, serum and bronchial specimens</li> </ul>
Cryptococcosis	As part of multiplex platforms in CSF samples	In process for FDA approval	<ul style="list-style-type: none"> <li>• Sensitivity not greater than antigen detection</li> <li>• Advantage is that test can be run on a smaller volume and multiplexed with other pathogens</li> </ul>
Pneumocystosis	MycAssay Pneumocystis, real-time PCR	CE marking 2010	<ul style="list-style-type: none"> <li>• 22% increase in sensitivity as compared to the Calcofluor white stain method used on bronchial lavage specimens</li> <li>• False positive rates may be high (46% in some studies with colonised patients)</li> </ul>



# 7

**QUALITY ASSURANCE**

## Quality Assurance

Imran Ahmed and Seema Irfan

Quality assurance aims to improve the accuracy, reliability, timeliness and reproducibility of information generated in a microbiology laboratory. Ultimately, it facilitates proper patient management, good laboratory practice, external accreditation and staff motivation. Consultants and senior technologists are responsible for quality management, and under their leadership, all staff should actively participate in QC programmes.

Quality assurance comprises of internal and external measures:

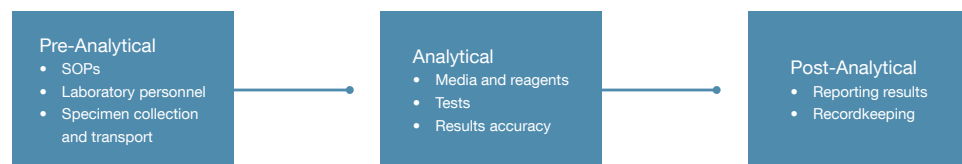
- Internal quality assurance
  - Monitors all phases of testing, including pre-analytical, analytical and post-analytical.
  - Accomplished by assessing the quality of specimens, monitoring the performance of test procedures, reagents, media, instruments and personnel by reviewing test results and documenting the validity of the test methods.
  - Identifies internal errors and helps in re-organisation of processes to ensure accuracy and reliability of results.
- External quality assessment
  - Compares a laboratory's testing performance to a source outside, such as a peer group of laboratories or a national reference laboratory.
  - Accomplished by proficiency testing, inter-laboratory rechecking or retesting of slides, and on-site evaluation.
  - Identifies hidden errors in testing and ensures reproducibility of results.

Box 7.1: Internal Quality Assurance versus External Quality Assessment	
Internal Quality Assurance	<ul style="list-style-type: none"> <li>• Performed <b>inside</b> the lab</li> <li>• Assesses accuracy and reliability of results</li> <li>• Identifies internal errors</li> </ul>
External Quality Assessment	<ul style="list-style-type: none"> <li>• Performed <b>inside and outside</b> the lab</li> <li>• Assesses reproducibility of results</li> <li>• Identifies hidden errors</li> </ul>

### Internal Quality Assurance

The basis is improving quality at each step in the laboratory workflow. Managers must invest time and resources to develop and implement standard operating procedures, hire competent staff, standardise tests, stock supplies and develop a record-keeping system.

Figure 7.1: Overview of internal quality assurance



### Standard Operating Procedures (SOPs)

- Maintain an SOPs binder in the laboratory that is accessible at all times to staff working on the premises.
- Develop and implement SOPs for every procedure performed in the laboratory using current guidelines and literature published in reputable journals and books.
- To ensure that SOPs reflect current scientific knowledge and trends, a consultant and technical supervisor must review, revise, date and initial documents at least once a year.

### Human Resource

- Based on the volume and complexity of work, a sufficient number of qualified supervisory and technical personnel must staff the laboratory.
- Document competencies of staff working in the laboratory at least twice a year.
- Offer lab personnel access to continuing education programmes periodically.
- Maintain personnel file for documentation related to staff.

### Specimen Collection and Transportation

- Ideally, collect specimens with sufficient coordination between laboratory staff and clinicians.
- Use a standardised specimen collection form to obtain relevant patient information from clinicians. Data collected should include at least the following:
  - Name (first and last)
  - Unique identifier (such as medical record number or government-issued identification card)
  - Age and sex
  - Clinical history
  - Site of specimen collection
  - Time of specimen collection
  - Information of other specimens submitted to laboratory
  - Patient contact details
- Develop SOPs for each specimen collected and test run, and include at least the following information:
  - Transport medium
  - Transport time
  - Holding temperature during transport
  - Availability and frequency of test in the laboratory (daily, bi-weekly, fortnightly, monthly)
  - Reporting schedule (daily, bi-weekly, fortnightly, monthly)

### Media, Reagents, Stains and Biochemical Reactions

- Apply labels on all containers clearly identifying the following:
  - Name of culture media, solution or reagents
  - Batch number
  - Date of preparation
  - Date of first in use
  - Expiry date
- Check performance of media and reagents against QC strains (see Table 7.1).
  - Maintain an inventory of mother stocks of QC organisms frozen at  $-70^{\circ}\text{C}$  in potato dextrose slants for indefinite period of time.
  - Maintain a set of QC strains at room temperature and sub-culture every 3 months.
  - Draw fresh isolates from the mother stock frozen at  $-70^{\circ}\text{C}$  once a year.
- Media should only be made available once sterility checks have been performed. Contaminated lots of media and solutions should be discarded. Results of sterility check should be kept in the section.
- Check performance of all stains using positive and negative control slides. Record, initial and date results on an appropriate form.
- Perform biochemical tests according to instructions outlined in the procedure manuals.
- Only report results for identification of organisms when the controls show expected result.
- Immediately report unsatisfactory results to the laboratory supervisor.
- Check all commercially prepared media, plates and tubes for cracks, clarity, excessive bubbles, hemolysis, unequal surface and filling, and visible contamination.

- To determine sterility of media prepared in-house, follow these steps:
  - At random, select 5% of plates prepared in each lot of media to be tested.
  - Incubate each half of the plates selected at 25°C and 35°C for 3 days.
  - Inspect those plates daily for contamination.
  - If 5% or less of the total plates are contaminated, the lot is acceptable for use.
  - If more than 5% of the total plates are contaminated, the lot is resampled.
  - If the resampled plates show greater than 5% contamination, the entire lot is assumed to be contaminated and should be discarded.

### Reporting Results

- All laboratory reports must be reviewed and countersigned by the supervisor.
- Prior to finalising results ensure the following:
  - No steps in testing were missed.
  - No clerical errors were made while collecting specimen or running the test.
  - Correct conclusions have been drawn.
  - Review comments.
  - Patient confidentiality was maintained.
  - Clinicians are informed of panic results.
  - Patient records will be maintained for at least 2 years.

### Archives and Recordkeeping

- Laboratory Staff are responsible for recording QC data on the appropriate forms.
- Supervisors (medical and technical) are responsible for monthly periodic review of the QC data.
- All QC records are required to be retained for a period of at least 2 years, including QC audits and QC indicators corrective action record.
- Weekly reviews by laboratory personnel (consultant and technical supervisor).
- Monthly reviews by laboratory head

### Safety in Mycology Laboratory

(see Chapter 8)

### External Quality Assessment

External quality assessment is an important indicator of laboratory performance. During EQA, laboratory procedures, reagents, media, equipment and personnel are all checked. Depending on availability of time and resources, EQA can be performed using the following methods:

- External proficiency testing
  - Unknown proficiency samples are sent to the laboratory for testing. Specimens should be processed within 1 day of arrival. In order to keep impartiality with the specimens submitted for proficiency, all specimens are to be treated as patient's specimens.
  - Final reports have to be reviewed and signed by the supervisor and director.
  - A lab must maintain an average score of 80% to maintain licensure in that subspecialty area.
- Rechecking or retesting
  - Previously read slides and tests are re-read and re-analysed by a reference laboratory.
- On-site evaluation
  - Done when external proficiency and rechecking/retesting methods are difficult.

**Table 7.1: ATCC strains for quality control**

For media prepared in-house, run with a new number each time. Otherwise the medium is exempt from quality control by user.

Media	Frequency of testing	Positive control ATCC	Negative control ATCC
Sabouraud's dextrose agar	With each batch	<i>C. albicans</i> 10231 or 60193 <i>T. mentagrophytes</i> 9533	<i>E. coli</i> 25922
Potato dextrose agar	With each batch	<i>A. fumigatus</i> 9197	<i>E. coli</i> 25922
BiGGY agar	With each batch	<i>C. albicans</i> 10231 <i>C. tropicalis</i> 750	<i>E. coli</i> 25922
Malt extract agar	With each batch	<i>A. niger</i> 9642 <i>C. albicans</i> 10231	Un-inoculated Media
<i>Aspergillus flavus</i> and <i>A. parasiticus</i> agar	With each batch	<i>A. flavus</i> 22547	<i>A. niger</i> 16404
Cornmeal Tween-80	With each batch	<i>C. albicans</i> 10231	<i>C. krusei</i> 6258
Urease agar	With each batch	<i>C. neoformans</i> 66031	<i>C. albicans</i> 60193
Germ tube test	Daily	<i>C. albicans</i> 14053	<i>C. tropicalis</i> 66029
Mycosel agar (cycloheximide tolerance)	With each batch	<i>T. mentagrophytes</i> 9533 <i>C. albicans</i> 10231	<i>A. niger</i> 16404
Dermatophyte test medium	With each batch	<i>T. mentagrophytes</i> 28188	<i>A. niger</i> 16404
Casein	With each batch	<i>Nocardia asteroides</i> (CDC B-2965) "Freddie"	<i>Streptomyces griseus</i> 38904
Tyrosine	With each batch	<i>N. asteroides</i> (CDC B-2965) "Freddie"	<i>S. griseus</i> 38904
Xanthine	With each batch	<i>N. asteroides</i> (CDC B-2965) "Freddie"	<i>S. griseus</i> 38904
India ink	Daily	<i>C. neoformans</i> 66031	<i>C. albicans</i> 60193
Hair perforation test	With each test	<i>T. mentagrophytes</i> 9533	<i>T. rubrum</i> 28122

Lactophenol cotton blue	Daily	<i>Penicillium</i> species and <i>Aspergillus</i> species	Solution without fungus
Calcofluor white stain	With each test	<i>Aspergillus</i> species and <i>Candida</i> species	Solution without fungus
10% KOH solution	With each test	Using a portion of a sputum specimen, ensure that the clinical material dissolves	Check the reagents prior to use. If cloudy, prepare new solution
Brain heart infusion (BHI) agar with 10% sheep blood slant	With each batch	<i>Histoplasma capsulatum</i>	Uninoculated slant
API 20C AUX	With each new lot number	<i>Trichosporon beigeli</i> 2744771	<i>C. glabrata</i> 2000040



# SAFETY IN THE MYCOLOGY LABORATORY

# Safety in the Mycology Laboratory

Erum Khan

Safety in the mycology laboratory is crucial because of the potentially pathogenic fungi being studied as well as the hazardous nature of reagents, flames, glassware and procedures. For safety and protection, senior supervisory staff should develop biosafety guidelines and ensure that all workers are well-versed with them. Ideally, biosafety guidelines should be science-based, made available broadly and be updated based on real-time feedback. Individual labs should further tailor these recommendations based on their own experiences.

## Box 8.1: Definitions

**Biorisk** is any harm where the source is a biological material

**Biorisk assessment** is an analysis of the severity and frequency of exposure to this harm

**Biorisk management** is the identification of biorisks, and steps towards its control and mitigation

## Box 8.2: Five steps of risk assessment

- Identify potential hazards
- Decide who is at risk
- Assess likelihood of harm
- Implement adequate precautions
- Manage risks and hazardous situations

## Pre-Analytical Phase Hazards

### Risk Factors

- Patients with any active, latent, chronic or undiagnosed infections can be a source of disease, and sample collection, handling and transport should always be performed carefully.

### Best Practices

- Only trained staff (phlebotomist, nurse or medical doctor) should collect samples – e.g. drawing blood, fine needle aspiration and punch biopsy – to avoid needlestick and prick injuries.
- Always perform skin scrapings and nail drilling in an isolated room or area of lab to avoid creating contaminated aerosols.
- Staff should wear personal protective equipment (PPE), such as mask, gloves and gown, as appropriate.

## Analytical Phase Hazards

### Risk Factors

- The most common laboratory-acquired fungal infections are those caused by dimorphic fungi *Blastomyces*, *Histoplasma* and *Coccidioides*. Most (LAIs) are secondary to inhalation of conidia.
- Ideally all specimens must be processed in a BSC observing safe practices.
- If a BSC is not available, specimen processing should be performed in an area of the laboratory with minimum traffic to avoid aerosol generation.
- Staff processing specimens must wear proper PPE and must be competent to handle the specimen according to good laboratory practices.

## Box 8.3: Common modes of lab-acquired infections

- Parenteral inoculations with syringes and sharps
- Splashes onto skin and mucus membranes
- Inhalation of aerosols
- Ingestion due to mouth pipetting or eating in laboratory
- Animal bites or scratches during animal studies

## Best Practices

### Highly Pathogenic Fungi

- Highly-pathogenic fungi include *H. capsulatum*, *B. dermatitidis*, *Coccidioides immitis*, *C. posadasii*, *Paracoccidioides brasiliensis*, *P. marneffeii*, and *C. bantiana*, and must always be handled in a BSL-3 facility.
- Avoid slide cultures and wet preparation of isolates that are suggestive of one of the above-listed pathogens.
- Such pathogens can either be sent to reference labs or identified using molecular techniques to avoid exposure.

### Material Safety Data Sheet

- MSDS is an essential document that contains information about the chemical nature and safe handling i.e. storage and disposal guidelines of products in the laboratory.
- These documents are prepared by the manufacturers of the material and provide end-user information for possible hazardous outcomes in case of accidents or over exposure.
- As part of good laboratory practice, every chemical/hazardous material placed in the laboratory must be accompanied with an MSDS sheet.
- Chemicals must be handled, saved and discarded as mentioned in these sheets. Data sets must be reviewed before chemical/hazardous material is used in the lab.
- Always look at the MSDS, match the chemical on the container with the MSDS, be aware of the hazards, safe handling and storage of the chemical, as well as what to do in an emergency involving it.

### Culture

- A complete risk assessment is recommended for an individual laboratory.
- Handle all cultures, especially molds (filamentous, fuzzy or cottony), in a Class II BSC placed in a separate room or a designated space in an open microbiology laboratory.
- Petri plates (particularly those growing mold) must be sealed with porous tape to prevent accidental opening and spread of spores.
- Cultures with yeast can be read on the open bench in a BSL-2 laboratory. However, if the isolate is suspected to be a dimorphic fungus (slow growing white or black molds) it must be shifted to Class IIA2 BSC for further manipulation or processing.
- Never sniff a fungal culture to determine its odor. Even on a bacteriology work-station, plates containing molds should not be uncovered on the open bench.
- Storage and transportation of filamentous molds to another laboratory must be done in slants with screw-cap tubes. Use of petri dishes is not recommended.
- *Coccidioides* spp. is the only fungus that is classified as a select agent. However, there are other highly-pathogenic fungi that require special handling.

### Reagents and Media

- Potential risks and mitigations steps in mycology laboratory include but not limited to below mentioned reagents and activities.
- Potassium hydroxide
  - KOH 10%-15% solution is corrosive and may cause burns or irritation to skin, eyes, and respiratory tract.
  - Avoid contact with eyes and skin, inhalation and ingestion.
  - Use of gloves and eye protection is recommended if there is a possibility of splashing or aerosol generation.
- Calcofluor white stain
  - It is not hazardous and hence no special safety measures are required.
  - Good hand hygiene using soap and water at the end of chemical handling is recommended.
  - In case of accidental eye contact, rinse eye well with water.
  - If KOH is used with Calcofluor white stain, more stringent precautions must be taken. Always refer to MSDS for guidance.

- Lactophenol cotton blue (Poirier's blue)
  - It is the most commonly used stain in the mycology laboratory.
  - Chemically, LPCB is acidic and therefore avoid contact with skin, eyes and clothing.
  - The product is considered hazardous in larger amounts, i.e., toxic by inhalation and contact with the skin, and especially if swallowed.
  - Handle large amounts of LPCB in a well-ventilated area.
- India ink
  - It is not a regulated hazardous waste in quantities used in clinical lab therefore no special personal protection is required under normal use conditions.
  - However, since yeast cells can remain viable, good hand hygiene and gloves are recommended when handling India Ink wet mounts.
- Gomori methenamine silver nitrate stain
  - Ingredients are toxic and corrosive therefore avoid contact with skin and eyes.
  - Large amounts must be handled with adequate ventilation system.
- Giemsa stain
  - Giemsa stain is toxic by inhalation, absorption and ingestion due to its methanol content.

#### Laboratory Design

- Laboratory design is fundamental to laboratory safety. Although there is no national standard requirement for area per person working in the laboratory, ideally, a minimum 5-foot space between the worker and any object behind her/him should provide enough room for movement between benches.
- The mycology section should be separated from the rest of the laboratory by closable doors.
- Although not imperative, airflow should be preferably directed inward from the main laboratory into the mycology lab.
- The section must also have a sink for hand washing. Bench-tops must be constructed of impervious materials.
- Mycology section must have restricted access, limited to staff only.

#### Biosafety Level 3 Laboratory

- Since most common laboratory-acquired fungal infections are caused by inhalation of conidia of dimorphic fungi *Blastomyces*, *Histoplasma*, and *Coccidioides*, BSL-3 is preferred.
- However, if BSL-3 facility is not available, use of BSC and respiratory precautions may be used with good laboratory practices.

#### Biosafety Cabinet

- Class II-A1 or II-A2 BSC is recommended for the diagnostic laboratory.
- It is recommended that BSC should be installed in the laboratory away from walking paths and doors.
- The BSC filter can get damaged at the glue joint or at the gasket if moved, resulting in dangerous leaks. Thus filter and cabinet integrity must be tested whenever the equipment is shifted.
- BSCs must be certified by trained professionals in accordance with ANSI/NSF Standard at time of installation and at least annually thereafter. In addition, recertification is recommended each time the unit is moved.

## Post-Analytical Phase Hazards

#### Risk Factors

- Generation of biohazard waste.

#### Best Practices

#### Disinfection

- All live cultures and waste generated must be autoclaved before discarding.
- If autoclaving is unavailable then fungal culture can be decontaminated by soaking the plates and tubes overnight in a fresh 1:10 bleach solution. The plates and opened tubes must be completely immersed overnight before discarding.
- Ethyl alcohol (70%) has been reported as the most effective concentration for killing the tissue phase of *B. dermatitidis*, *C. immitis*, and *H. capsulatum*.
- Chlorine-based disinfectants such as hypochlorite and household bleach (>0.5%) can also be used but these are corrosive and must be wiped effectively from metallic surface.

#### Waste Management

- Laboratory must have a waste management plan that identifies and categorises waste as infectious and non-infectious at the site of waste generation.
- Strategies must be in place to differentiate between categories of waste such as use of colour-coded waste bags.
- All infectious waste must be either autoclaved or disinfected before it leaves the laboratory.
- At BSL-3 labs all culture and stocks must be autoclaved before discarding.
- For BSL-2 pathogens, cultures must be either disinfected or sealed in leak-proof containers to be incinerated, either on-site or at distant location, such as local government contractual agreements.

**Table 8.1: Common hazardous activities specific to mycology laboratory that can put workers at risk**

Activity	Potential hazard/route of transmission	Engineering control	Administrative control/work practice	PPE	Comments
Respiratory samples inoculation	Aerosol generation, inhalation	BSL-2 laboratory, use of BSC	Work inside BSC with splash shield	Gloves, mask and laboratory coat	Risk of fungal, MTB and viral infections
Skin/tissue biopsies	Sharp injury, percutaneous inoculation	Use of protected sharps; puncture resistant sharp container	Work inside BSC with splash shield; immediate discard in punctured resistant bin	Gloves, mask and laboratory coat	If BSC is not available then clean bench at rear end of lab, skilled worker
Sub-culture from blood culture bottle	Sharp injury, percutaneous inoculation	Use safe sharps such as retractable needles; puncture resistant sharp container	No recapping; immediate disposal of sharp in bin	Gloves, mask and laboratory coat	Do not over fill sharp discard container
Centrifuge	Aerosol generation, inhalation	Use BSC, removable safety rotors, safety cups and plastic tubes	Load and unload rotors in BSC, and open lid when completely stopped; no glass tubes	Gloves, mask and laboratory coat	Checks lids for wear and tear
Smear/stain	Aerosol slide warming, inhalation	Use slide warmer	Do not heat smear directly on flame	Gloves and laboratory coat	Some stains are toxic and corrosive see above; avoid contact with skin and eyes
Fungal wet mounts (KOH-Calcofluor)	Toxic inhalation and direct skin, mucus contact	Use well-ventilated room	For storage of large volumes use fumes hood or properly ventilated room	Laboratory coat, glove, and mask when dealing with large volumes	These are toxic and corrosive avoid contact with skin and eyes
Reading fungal culture plates	Aerosol generation, inhalation, direct inoculation	Use BSC for all molds; yeast can be processed on bench	Secure petri dish lid with adhesive tape	Laboratory coat, gloves and mask if handling mold outside BSC	Do not sniff fungal cultures at any point, do not open plate with mold on open bench

## Glossary

Term	Definition
Aleuriospore	A fungal spore formed at the end of a hypha
Anamorph	An asexual (imperfect) stage of fungus
Arthrospore	A spore formed from fragmentation of a hypha into individual cells
Ascocarp	A large fruiting body harboring asci, e.g. in <i>Chaetomium</i> spp.
Ascus	A sac-like structure often formed in a fruiting body and usually contains 2-8 ascospores
Ascospore	Sexual spore produced in an ascus
Aseptate	A hypha without cross-walls or septa
Asynchronous	Pertaining to conidiation; conidia are produced in succession from the same single fertile point; the conidia may form short chains or gather in loose clusters
Blastic	Describes the spores formed by the enlargement of the spore-producing cell before the septum is produced
Blastoconidium	A conidium formed by budding along a hypha, pseudohyphae or single cell as in yeasts
Chlamydospore	A resting spore formed from the enlargement of an existing cell
Cleistothecia	Closed fruiting body containing asci
Conidiogenesis	Process leading to the production of conidia (spores)
Conidiophore	A specialised cell or hypha on which spores are formed
Conidium	An asexual spore
Coremia	Compact cluster of erect conidiophores
Dysgonic	Slow growing
Enteroblastic	The formation of spores in succession from a spore-producing cell
Floccose	Covered with woolly tufts or soft hair
Hilum	Attachment scar, formed where the conidium was attached to the conidiophore
Holoblastic	Production of a conidium with all layers of the mother cell wall
Hülle cells	Large thick-walled multinucleated cells formed by some <i>Aspergillus</i> species
Hypha	An individual filament that makes up the vegetative growth of a fungus
Macroconidia	A large conidium (asexual spore) produced by fungi usually multicellular
Metula	Cell or short branch on vesicle bearing phialides
Microconidia	A small conidium (asexual spore) produced by fungi usually multicellular
Mold	A filamentous fungus

Term	Definition
Mycelium	A mass of hyphae (branching filaments) that make up the vegetative growth of a fungus
Ostiole	A mouth or opening
Perithecium	Large round or pear-shaped structure containing asci and ascospores that are released through an ostiole
Phialides	Cell with terminal opening through which enteroblastic conidia are produced repetitively
Pseudohypha	Chain of yeast cells that have been produced by budding and have remained attached to one another forming a hypha-like filament
Pseudomycelium	A mass of pseudohyphae
Pycnidium	Large oval, round or flask-shaped fruiting body containing conidia; usually has an ostiole
Reflexive	A hyphal branch that grows inwards towards the centre of the colony
Rhizoid	A root-like branching hypha
Septate	Having cross walls or septa
Septa	A cross wall in a fungal hypha or spore
Sporangiophore	Specialised hyphal branch or stalk bearing a sporangium
Sporangium	Closed sac-like structure in which asexual spores (sporangiospores) are formed by cleavage
Stipe	Conidiophore bearing vesicle in <i>Aspergillus</i>
Sympodial	Pertaining to the growth of a conidiophore; the conidia arising from the same conidiophore are seen in various stages of development. These conidiophores are typically geniculate in appearance
Synchronous	Pertaining to conidiation; conidia are formed simultaneously, each arising from a separate fertile point; these points are often very close together, producing clusters of conidia (conidia in a cluster are in the same stage of development)
Synnemata	Compact cluster of erect conidiophores
Teleomorph	The sexual (perfect stage) of a fungus
Thallic	Spores produced from an existing hypha
Yeast	Unicellular budding organism
Zygospor	A thick walled sexual spore produced by zygomycetes

## References and Resources

### Chapter 1 | Sample Collection and Transport

- Campbell, Colin K., Elizabeth M. Johnson, and David W. Warnock. *Identification of Pathogenic Fungi*, 2nd ed. Chichester, West Sussex [u.a.]: Wiley-Blackwell, 2013.
- Larone, Davise H. *Medically Important Fungi: A Guide to Identification*, 5th ed. Washington, DC: American Society for Microbiology Press, 2011.

### Chapter 2 | Media and Tests

- Campbell, Colin K., Elizabeth M. Johnson, and David W. Warnock. *Identification of Pathogenic Fungi*, 2nd ed. Chichester, West Sussex [u.a.]: Wiley-Blackwell, 2013.
- Pincus, Dave H., Sylvain Orega, and Sonia Chatellier. "Yeast identification – past, present, and future methods." *Medical Mycology* 45, no. 2 (2007), 97-121. doi:10.1080/13693780601059936.
- Procop, Gary W., Franklin R. Cockerill III, Emily A. Vetter, W. S. Harmsen, John G. Hughes, and Glenn D. Roberts. "Performance of Five Agar Media for Recovery of Fungi from Isolator Blood Cultures." *J Clin Microbiol* 38, no. 10 (October 2000), 3827-3829.

### Chapter 3 | Diagnosis of Fungal Infections

- Campbell, Colin K., Elizabeth M. Johnson, and David W. Warnock. *Identification of Pathogenic Fungi*, 2nd ed. Chichester, West Sussex [u.a.]: Wiley-Blackwell, 2013.
- De Hoog, Sybren, Josep Guarro, Josepa Gené, and Maria J. Figueras. *Atlas of Clinical Fungi*. Utrecht: Centraalbureau voor Schimmelcultures, 2000.
- Jorgensen, James H., Michael A. Pfaller, and Karen C. Carroll. "General Approaches for Direct Detection and Identification of Fungi." In *Manual of Clinical Microbiology*, 11th ed. American Society Microbiology Press, 2015.
- Larone, Davise H. *Medically Important Fungi: A Guide to Identification*, 5th ed. Washington, DC: American Society for Microbiology Press, 2011.

### Chapter 4 | Antifungal Susceptibility Testing

- Alastruey-Izquierdo, Ana, Marcia S. Melhem, Lucas X. Bonfietti, and Juan L. Rodriguez-Tudela. "Susceptibility Test for Fungi: Clinical and Laboratorial Correlations in Medical Mycology." *Revista do Instituto de Medicina Tropical de São Paulo* 57, no. 19 (2015), 57-64. doi:10.1590/s0036-46652015000700011.
- European Committee on Antimicrobial Susceptibility Testing. "Antifungal Susceptibility Testing (AFST)." EUCAST. Accessed July 16, 2017. [http://www.eucast.org/antifungal\\_susceptibility\\_testing\\_afst/](http://www.eucast.org/antifungal_susceptibility_testing_afst/).
- Johnson, Elizabeth M., and Maiken Cavling-Arendrup. "Susceptibility Test Methods: Yeasts and Filamentous Fungi." In *Manual of Clinical Microbiology*, 11th ed., 2255-2281. Washington DC: American Society of Microbiology Press, 2011.
- Jorgensen, James H., and John D. Turnidge. "Susceptibility Test Methods: Dilution and Disk Diffusion Methods." In *Manual of Clinical Microbiology*, 11th ed., 1253-1273. Washington, DC: American Society for Microbiology Press, 2011.
- Lockhart, Shawn R., and David W. Warnock. "Antifungal agents and susceptibility test methods." In *Manual of Clinical Microbiology*, 11th ed., 2223-2235. Washington, DC: American Society for Microbiology Press, 2011.
- Perlin, David S. "Mechanisms of Resistance to Antifungal Agents." In *Manual of Clinical Microbiology*, 11th ed., 2236-2254. Washington, DC: American Society for Microbiology Press, 2011.
- Pfaller, Michael A. "Antifungal Susceptibility Testing." Evidence-Based Clinical Decision Support at the Point of Care | UpToDate. Accessed July 16, 2017. <http://www.uptodate.com/contents/antifungal-susceptibility-testing>.
- Rex, John H., and Mahmoud A. Ghannoum. *M27A3E | Reference Method for Broth Dilution Antifungal Susceptibility Testing of Yeasts (Electronic Document)*. The Clinical & Laboratory Standards Institute, 2008. <https://clsi.org/standards/products/microbiology/documents/m27/>.

**Chapter 5 | Antigen-based Tests for the Diagnosis of Fungal Infections**

- Associates of Cape Cod, Inc. "Clinical Diagnostics Fungitell Assay." Associates of Cape Cod, Inc. Accessed July 15, 2017. <http://www.acciusa.com/clinical/fungitell/index.html>.
- Bio-Rad. "Platelia Aspergillus EIA | Clinical Diagnostics | Bio-Rad." Bio-Rad | Products for Life Science Research & Clinical Diagnostics. Accessed July 15, 2017. <http://www.bio-rad.com/en-us/product/mycology/platelia-aspergillus-ag>
- Jorgensen, James H., Michael A. Pfaller, and Karen C. Carroll. "General Approaches for Direct Detection and Identification of Fungi." In *Manual of Clinical Microbiology*, 11th ed. American Society Microbiology Press, 2015.
- Kozel, Thomas R., and Brian Wickes. "Fungal Diagnostics." *Cold Spring Harbor Perspectives in Medicine* 4, no. 4 (2014), 19299-19299. doi:10.1101/cshperspect.a019299.

**Chapter 6 | Molecular Methods for the Diagnosis of Fungal Infections**

- Arvanitis, M., T. Anagnostou, B. B. Fuchs, A. M. Caliendo, and E. Mylonakis. "Molecular and Nonmolecular Diagnostic Methods for Invasive Fungal Infections." *Clinical Microbiology Reviews* 27, no. 3 (2014), 490-526. doi:10.1128/cmr.00091-13.
- Jensen, Rasmus H., and Maiken C. Arendrup. "Molecular diagnosis of dermatophyte infections." *Current Opinion in Infectious Diseases* 25, no. 2 (2012), 126-134. doi:10.1097/qco.0b013e32834f5f6e.
- Procop, Gary W. "Molecular Diagnostics for Invasive Fungal Infections." *The Journal of Molecular Diagnostics* 12, no. 1 (2010), 17-19. doi:10.2353/jmoldx.2010.090173.
- Shuetz, AN. "Invasive fungal infections: biomarkers and molecular approaches to diagnosis." *Clin Laboratory Med* 33 (2013), 505-525.
- Zhang, Sean X. "Enhancing molecular approaches for diagnosis of fungal infections." *Future Microbiology* 8, no. 12 (2013), 1599-1611. doi:10.2217/fmb.13.120.

**Chapter 7 | Quality Assurance**

- Campbell, Colin K., Elizabeth M. Johnson, and David W. Warnock. *Identification of Pathogenic Fungi*, 2nd ed. Chichester, West Sussex [u.a.]: Wiley-Blackwell, 2013.
- World Health Organization, Clinical and Laboratory Standards Institute, Centers for Disease Control and Prevention (U.S.). *Laboratory Quality Management System: Handbook*. 1.1 ed. France: World Health Organization, 2011.

**Chapter 8 | Safety in the Mycology Laboratory**

- Miller, J. Michael. *Guidelines for Safe Work Practices in Human and Animal Medical Diagnostic Laboratories: Recommendations of a CDC-Convended, Biosafety Blue Ribbon Panel*. [Atlanta, GA]: U.S. Department of Health and Human Services, Centers for Disease Control and Prevention, 2012.

**Index****A**

*Absidia corymbifera*, 53  
*Absidia* spp., 53, 91  
*Acremonium* spp., 64  
*Actinomyces*, 6, 71  
 Actinomycetes, 14, 22  
 Acute, 22, 42, 45, 46, 50  
 Aflatoxin, 42  
*A. fumigatus*, 15, 41, 44, 45, 101  
 Allergic, 45  
*Alternaria* spp., 72, 73, 74  
 Amphotericin, 26, 33, 50, 84, 85, 86  
 Angioinvasive, 41, 50, 51  
 Antifungal susceptibility, 14, 83, 84, 85, 87, 113  
*Apophysomyces* spp., 53  
 Arthroconidia, 22, 72  
 Arthrospore, 17  
 Ascospores, 66, 108, 109  
 Aseptate, 11, 22, 52, 108  
 Aspergilloma, 42  
*Aspergillus flavus*, 11, 46  
*Aspergillus nidulans*, 47  
*Aspergillus niger*, 49  
*Aspergillus terreus*, 48

**B**

*Basidiobolus* spp., 54, 55  
 BiGGY agar, 10, 12, 27, 28, 29, 30, 31, 32, 33, 101  
*Bipolaris* spp., 72, 73, 74  
 Blastoconidia, 12, 26, 27, 28, 29, 30, 31, 32, 38  
 Bronchoalveolar lavage, 4, 7, 92  
 Budding yeast, 25, 26, 31, 32, 35, 36, 40, 78

**C**

Calcofluor, 6, 7, 8, 40, 44, 95, 102, 105, 107  
*Candida albicans*, 8, 12, 13, 14, 15, 18, 23, 25, 26, 27, 28, 86, 101  
*Candida auris*, 33  
*Candida guilliermondii*, 32  
*Candida lusitanae*, 31  
*Candida parapsilosis*, 28  
*Candida tropicalis*, 27  
 Candidiasis, 23, 24, 25, 29  
*Capnocytophaga*, 90  
 Caspofungin, 84  
*C. bantiana*, 75, 105  
*C. carnionii*, 75, 76  
 Cerebrospinal fluid, 11  
*C. glabrata*, 13, 23, 29, 86, 102  
*Chaetomium*, 80, 108  
 Chlamydoconidia, 22, 82  
 Chlamydospore, 12, 17  
 Chromobalstomycoses, 69, 70  
 Chromoblastomycosis, 75, 78  
 Chromoblastomycosis, 70  
*C. krusei*, 12, 13, 18, 23, 30, 86, 87, 101  
*Coccidioides* spp., 12, 104, 105, 106  
 Collarette, 78

Conidia, 14, 16, 42, 45, 46, 48, 49, 64, 66, 67, 68, 69, 72, 73, 74, 75, 76, 77, 78, 79, 81, 82, 105, 106, 108, 109  
*Conidiobolus* spp., 54, 55  
 Conidiophore, 108, 109  
 Cornmeal tween, 11, 10  
*C. parapsilosis*, 23, 28, 86, 87  
*C. pelliculosa*, 23  
*Cryptococcus* spp., 14, 8, 18, 22, 34, 36, 37, 40, 84, 85, 91  
*Cryptococcus neoformans*, 14, 34  
*C. tropicalis*, 13, 18, 26, 27, 28, 86, 101

**D**

Dematiaceous fungi, 69  
*Drechslera* spp., 73, 74

**E**

Echinocandins, 26, 33, 84, 85  
*E. dermatitidis*, 78  
*E. jeanselmei*, 77  
 Encapsulated, 8, 22  
 Endocarditis, 23, 25, 28  
 Endospores, 22  
 Endothrix, 5  
 Enriched media, 10  
*Escherichia coli*, 7  
 Esophagitis, 23  
 Eumycetomas, 69, 70  
 Extracellular, 22

**F**

Fluconazole, 23, 33, 58, 84, 86, 95  
*Fonsecaea pedrosoi*, 78  
*Fonsecaea* type, 78  
 Fungal ball, 42, 63  
*Fusarium* spp., 63, 65

**G**

Germ tube test, 13, 101  
 Graphium, 66

**H**

Health care, 8, 75  
*Histoplasma* spp., 12, 102, 104, 106  
 Hyaline, 22, 55, 63, 67, 76, 80, 81  
 Hyalohyphomycosis, 63

**I**

Intertrigo, 24  
 Intracellular, 22

**K**

Keratitis, 42, 44  
 KOH, 11, 6, 7, 8, 25, 44, 52, 71, 72, 102, 105, 107

**L**

Lactophenol Cotton Blue, 8, 102, 106

**M**

*Madurella grisea*, 82  
*Madurella mycetomatis*, 82  
*Malassezia furfur*, 40, 58  
*Malassezia* species, 40  
*M. audouinii*, 55  
*M. canis*, 55, 58  
*M. equinum*, 55  
*M. fulvum*, 55  
*M. gypseum*, 55, 59  
*Microsporium* spp., 16, 55, 58, 59  
*Microsporium canis*, 58  
Molecular methods, 15, 93, 94, 95, 113  
Mucocutaneous candidiasis, 23, 24  
Mucorales, 12, 50, 52, 54  
Mucormycosis, 43, 50, 51  
*Mucor* spp., 53, 91  
Mycetoma, 64, 66, 71, 72

**N**

*Nocardia* spp., 6, 17, 22, 71, 101

**O**

Onychomycosis, 32, 48, 62, 69, 73, 80  
Otitis externa, 23

**P**

*Paecilomyces lilacinum*, 67  
*Paecilomyces variotii*, 67  
PAF, 11, 6, 7  
Partial acid fast, 11  
Phaeohyphomycosis, 79  
Pheohyphomycoses, 69, 70  
*Phoma* spp., 81  
Pigmented hyphae, 63, 71, 81  
Pityriasis versicolor, 58  
Pseudohyphae, 12, 13, 17, 22, 23, 25, 26, 27, 28, 30, 31, 32, 33, 36, 39, 41, 108, 109  
Pulmonary aspergillosis, 41  
*Purpureocillium lilacinum*, 67

**Q**

Quality control, 10, 12, 13, 14, 15, 16, 87, 101

**R**

Rhinocerebral mucormycosis, 43, 50  
*Rhinocladiella* spp., 78, 79  
*Rhinocladiella mackenziei*, 79  
*Rhizopus* spp., 53, 91  
*Rhodotorula* spp., 40

**S**

*Saksenaea vasiformis*, 53  
*S. apiospermum*, 63, 66  
Saprophytic, 10, 15, 16, 17, 74  
*S. boydii*, 66  
*Scedosporium* spp., 63, 66

*Scedosporium apiospermum*, 63, 66  
Sclerotic bodies, 69, 70  
*Scopulariopsis* spp., 69  
Scotch tape, 4, 8, 16  
Selective media, 7, 15  
Septate, 44, 45, 46, 48, 64, 65, 66, 69, 72, 77, 80, 109  
Specimen collection, 14, 1, 2, 3, 5, 7, 99  
*Sporothrix schenckii*, 76  
*S. prolificans*, 66  
Sputasol, 6  
*Syncephalastrum* spp., 54

**T**

Tape preparation, 16  
Tease mount preparation, 14, 16  
Tinea, 5, 24, 40, 58, 61, 62, 82  
Tinea concentricum, 57  
Tinea corporis, 55, 56, 57  
Tinea faciei, 57  
Tinea pedis, 24, 61, 62  
Tinea unguinum, 55  
*T. mentagrophytes*, 8, 15, 16, 18, 55, 61, 101  
Tracheobronchitis, 42  
Transport, 14, 1, 2, 3, 5, 7, 99, 113  
Transportation, 2, 4, 105  
Triazoles, 26  
*Trichopton mentagrophytes*, 61  
*Trichophyton* spp., 14, 16, 55, 60, 61, 62  
*Trichophyton rubrum*, 60  
*Trichosporon* spp., 39, 90  
*T. rubrum*, 18, 55, 60, 101  
*T. tonsurans*, 55, 61, 62  
*T. verrucosum*, 55  
*T. violaceum*, 55, 62

**U**

Unicellular, 109  
*Ustilago (Pseudozyma)* spp., 41

**V**

Voriconazole, 84

**W**

Wide-angled branches, 22  
Workers, 75, 104, 107

**Y**

Yeasts, 14, 12, 13, 16, 17, 22, 23, 25, 31, 33, 35, 36, 38, 84, 90, 95, 108, 113

Practical Guide and Atlas for the  
**Diagnosis of Fungal Infections**

**Contributors**

Afia Zafar  
Kauser Jabeen  
Joveria Farooqi  
Saadia Tabassum  
Zafar Sajjad  
Seema Irfan  
Mohammad Zeeshan  
Erum Khan  
Sadia Shakoor  
Imran Ahmed

